

# Article ▶ Vision Training to Improve a Consecutive Exotropia: A Case Study with a 14-year-old Female Athlete

Joseph F. Clark, PhD, ATC, University of Cincinnati Departments of Neurology and Rehabilitation Medicine, Cincinnati, Ohio

Gerald M. Holloway, University of Cincinnati Athletics and NovaCare Rehabilitation, Cincinnati, Ohio

Hagar T. Elgendy-Peerman, University of Cincinnati Division of Sports Medicine, Department of Orthopaedic Surgery, Cincinnati, Ohio

James K. Ellis, OD, University of Cincinnati Athletics and NovaCare Rehabilitation, Cincinnati, Ohio

## ABSTRACT

**Background:** A multitude of ophthalmic treatment and management strategies have been successful for the treatment of exotropia, some of which include home-based exercise programs and vision training programs. Vision training has been found to be successful in improving stereovision, giving patients the ability to see in 3D, and for convergence insufficiency.

**Case Report:** This report describes a 14-year-old female athlete presenting with post-operative left eye exotropia with hyperphoria who was not able to appreciate stereopsis. A personalized action plan was designed to minimize suppression and to improve left-right ocular motor symmetry, which included home exercises and structured vision training. In the 29-week program, stereopsis improved from 0.00 mm to 16.00 mm. With regular vision training, the patient demonstrated improved stereopsis, decreased suppression, better precision of fixation, improved eye discipline of the left eye, and better coordination of both eyes. Ultimately, she was able to appreciate 3D.

**Conclusions:** Vision training, as part of the post-corrective surgery rehabilitation program, can restore the ability to see in 3D. Vision training for consecutive exotropia and rehabilitation of stereoscopic vision can be achieved without interrupting sports-specific activities and competitive play.

**Keywords:** Brock string, exophoria, heterophoria, hyperphoria, saccade, strabismus, suppression vision training

## Introduction

A multitude of ophthalmic treatment and management strategies have been successful for the treatment of exotropia, some of which include home-based exercise programs and vision training programs.<sup>1-5</sup> Vision training has been found to be successful in improving stereovision, giving the patient the ability to see in 3D.<sup>6</sup> This case report presents the methods and time course for a vision training regimen used to treat a patient with a consecutive exotropia.

## Case Report

A 14-year-old female soccer athlete and her mother initiated contact with the University of Cincinnati's Sports Medicine Department to improve sports performance through vision training. During the time of the interview, the patient was noted to have a left exotropia that was found to be the result of surgery for an esotropia four years earlier.<sup>7-9</sup> At this time, she was noted to lack stereoscopic vision, resulting in an inability to see 3D.

In obtaining the patient's medical history, we learned that this patient was born with left and right eye strabismus. At nine months old, the patient underwent her first surgery OU to repair the exotropia and was instructed that a second surgery might be needed in the future. The surgery was declared

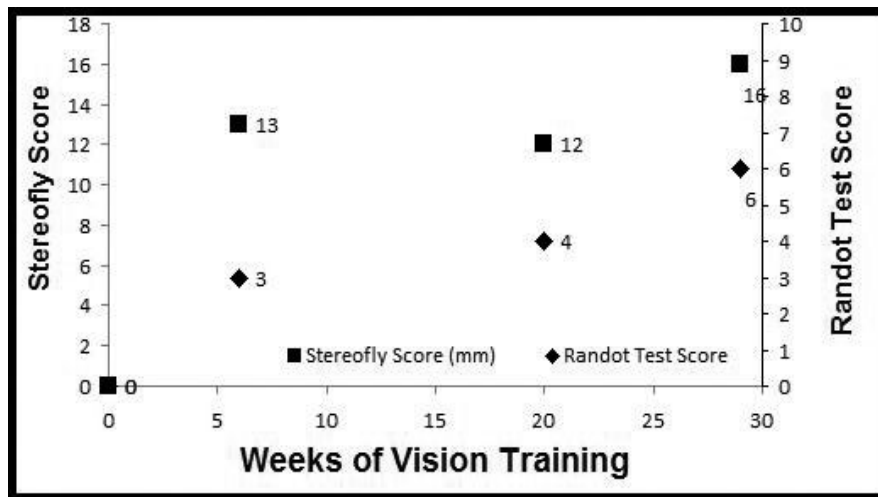
successful, as both eyes were adjusted to matching positions. Subsequently, the exotropia in the left eye returned. A second surgery was performed when the patient was ten years old, but no improvement was seen. According to previous physician's notes, the Stereo Fly score was recorded as 0 two years following the surgery. The exotropia following surgical over-correction was then untreated for the subsequent two years, with no improvement noted. One year prior to the vision training program, her visual acuity was noted as 20/20 OD, OS.

We performed a series of examinations prior to the start of vision training. These included a vision exam, acuity and phorias, a Dynavision exam,<sup>10</sup> stereopsis, and an ocular motor assessment.

## Initial Clinical Observations

In the initial clinical observations, the patient presented with a left eye exo-hypertropia. She was found to suppress the left eye, while her right eye was noted to be dominant. Cover testing showed that her eyes deviated up and out. Her visual acuity was 20/20 for both eyes, while her prescription was recorded as -1.50+0.50x045 OD and -2.75+2.75x120 OS.

Stereo Fly was 0, and Randot was 0/10 (Figure 1). A higher number in mm for the Stereo Fly is indicative of better stereopsis.<sup>6</sup> Brock string showed substantial suppression, with



**Figure 1.** Stereo Fly and Randot test scores' progress during the weeks of the training program.



**Figure 2.** Picture of the Bates Field Splitter glasses. These glasses are worn with the central visual field split by a card with different colors on either side. The subjects are advised to see both colors. Once they are comfortable with the glasses, they are engaged in pitch-and-catch with a soccer or football. They must track the ball and still see both colors. This method prevents suppression and disciplines the eyes to work together while restricting part of the cross-talk of the signal at the optic chiasm.

only one string observed, while saccades showed substantial left-right ocular motor differences, with the left being hypometric. Based on these results, an action plan was developed.

## Treatment

The initial action plan included daily Brock string and saccades at home. Brock string and saccades were to be performed binocularly and monocularly for one minute each.<sup>11</sup> The mother was asked to record the results for the saccades. The patient was scheduled to come in for training and rehabilitation once per week. The initial rehabilitation sessions were abbreviated to prevent fatigue or refractory symptoms related to the training.<sup>12,13</sup>

The action plan was designed to minimize suppression, to improve left-right ocular motor symmetry with the goal of improving stereoscopic vision, and to improve ocular motor performance. The patient was scheduled for once-weekly therapy sessions and given daily home exercises.

Home exercises were Brock string for one minute binocularly and monocularly and saccades with left eye

abduction minimized for one minute monocularly and binocularly.<sup>10</sup> In an effort to engage in dynamic adduction of the affected eye with accommodation, we routinely use a monocular Brock string activity. This technique improves the endurance of the affected eye and can serve as a means to monitor the symmetry of the left/right eye performance. Therapy sessions included Dynavision, strobe glasses, and sports-specific pitch-and-catch with various training glasses monocularly and binocularly.<sup>10,14,15</sup> The training glasses included Bates field dividers, pinhole glasses, and vertical slit glasses (Figure 2).<sup>10,13,14</sup>

Pitch-and-catch exercises were done using a soccer ball with different glasses on (Bates glasses, strobe glasses, etc.). Similar pitch-and-catch exercises were also done with colored balls, a Marsden ball, the Nike Sparq trainer, Bates glasses with field dividers, pinhole glasses, and vertical slit glasses.<sup>11,14</sup> Often, pitch-and-catch was done either centered or off-center to the right in order to encourage left adduction and tracking. Bates glasses were of differing colors, and the patient was advised to be able to 'see' both colors at all times in order to practice fusion.<sup>6,16</sup>

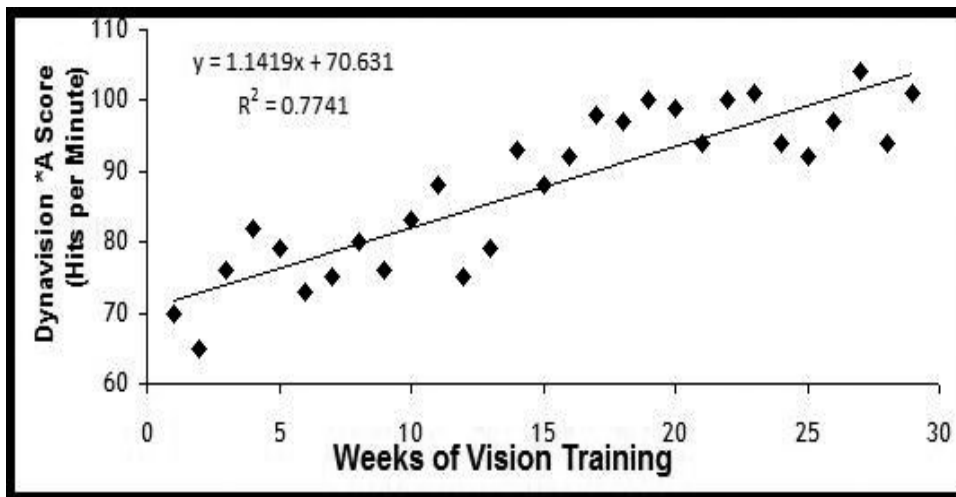


Figure 3. Relationship of Dynavision \*A weekly scores to weeks of the training program.

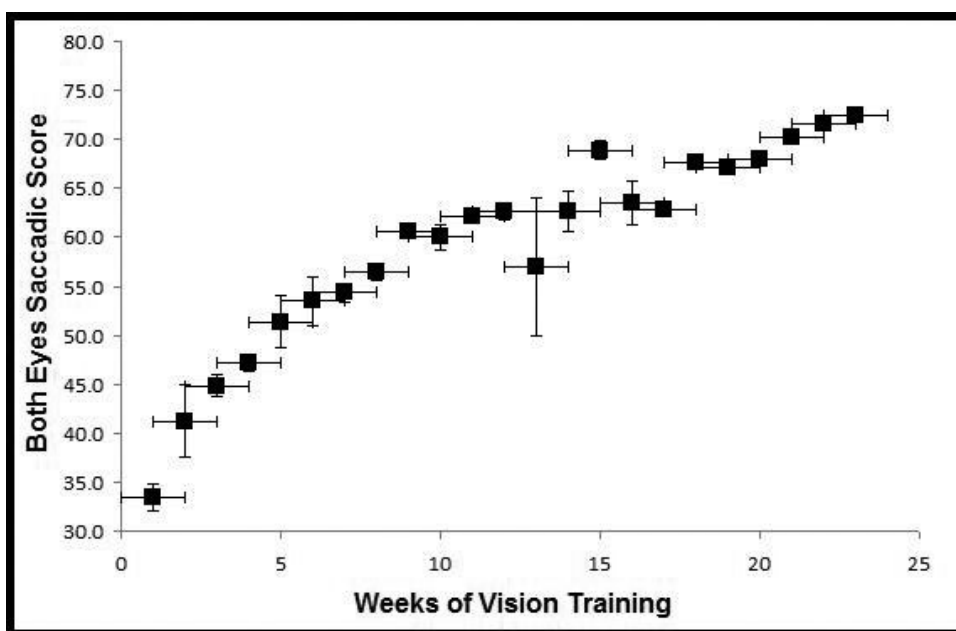


Figure 4. Results from the home saccadic eye movement for both eyes.

Vertical slit glasses were used with a 3 mm vertical slit on the left eye to encourage the left eye to adduct. The right side had either a horizontal slit, a horizontal line, or a blank color. The patient was advised to see with both eyes, with the left eye vertical slit gradually moved inward to enhance left adduction.

To perform the rehabilitation and training, we used standard methods that have been previously published.<sup>10,17-19</sup> These include Dynavision, Brock string, saccades, Marsden ball, strobe glasses, accommodation training, vergence training, and pinhole glasses.<sup>11,14</sup> Each rehabilitation session was designed to keep the patient engaged and to achieve ocular motor conditioning.

### Training and Rehabilitation Methods

The first few rehabilitation sessions were cut short at 20 to 30 minutes to mitigate evoking symptoms and fatigue, as well

as to assess the intensity of the rehabilitation sessions. After consulting with the patient and mother concerning fatigue and discomfort, subsequent sessions were for the full one hour.

### Vision Training

Week 2: After initiating the vision training, the patient reported regularly seeing two strings with the Brock string, which is normal and consistent with decreased suppression. The Dynavision baseline exam was recorded as 70 hits per minute (hpm) for both eyes in the \*A program, which significantly improved to 86 hpm at two weeks ( $p \leq 0.001$ ; Figure 3). The home saccadic eye exercise weekly average also significantly improved ( $p \leq 0.001$ ). Saccades were performed in one-minute increments, and the number of cycles per minute (cpm) was recorded. The results improved from  $33.4 \pm 1.4$  cpm for both eyes at the 0 week marker to  $41.3 \pm 3.7$  cpm after two weeks,

**Table 1. Vision Training Results – Initial and at the End of Training**

Vision Training Component	Initial	End of Training
Stereo Fly	0 mm	16 mm
Randot	0/10	6/10
Dynavision both eyes	70 hpm	101 hpm
Saccades both eyes	33.4±1.4 cpm	68.0±0.3 cpm

hpm: hits per minute, cpm: cycles per minute

from 34.1±1.6 at week 0 to 38.5±1.6 cpm for the right eye, and from 33.0±1.8 to 39.5±1.8 cpm for the left eye ( $p \leq 0.001$ ; Figure 4).

Week 4: Vision training sessions were altered to include added ocular motor and depth perception training with near/far and Brock string training.<sup>6,13,17</sup>

Week 6: Stereopsis was re-evaluated using the Stereo Fly and was found to have significantly improved from 0.00 mm to 13 mm (Figure 1). The patient's Randot score also improved from 0/10 to 3/10 (Figure 1). At this time, the patient and mother were given an assignment to watch a 3D movie in 40-minute increments. The patient's home saccadic scores significantly improved to 53.5±2.5 cpm for both eyes, to 50.8±2.6 cpm for the right eye, and to 50.8±3.2 cpm for the left eye ( $p \leq 0.001$ ; Figure 4). The patient's Dynavision \*A score for both eyes was 73 hpm.

Week 7: The patient enjoyed her first 3D movie in two sittings on consecutive nights.

Week 12: The patient spent four days at soccer camp. She suffered a direct hit to the left face/eye from a soccer ball. All vision training was suspended for one week while recuperating and performing re-evaluations. In Figure 4, a decrease in saccades is noted. It is not clear whether this is the result of a concussive event or from the vision training hiatus. Nonetheless, she quickly recovered and achieved pre-hit saccade values. At 13 weeks of rehabilitation, sessions were restarted following soccer camp. Saccades continued to improve: 57.0±7.0 cpm, while the right eye average was recorded as 57.5±2.5 cpm and the left eye as 53.5±0.5 cpm ( $p \leq 0.001$ ; Figure 4). Thus, there were no setbacks from the concussive event.

Week 20: Stereopsis was re-evaluated; the Stereo Fly was 12 mm and Randot was 4/10 (Figure 1). Weekly saccade scores were 68.0±0.3 cpm for both eyes, 67.8±0.5 cpm for the right eye, and 67.3±0.2 cpm for the left eye (Figure 4). The Dynavision \*A weekly score continued to improve to 99 hpm for both eyes (Figure 3).

Week 29: The patient received her exit interview. Stereopsis was re-evaluated and had improved to 16 mm, while her Randot score was evaluated at 6/10 (Figure 1). The Dynavision \*A score for both eyes at this point showed a significant improvement, from a baseline of 70 hpm at the start of the vision training program to 101 hpm ( $p \leq 0.001$ ; Figure 3).

## Discussion

In this case study, the vision training program and results for a 14-year-old girl with consecutive exotropia and an absence of stereoscopic vision were presented (Table 1). The patient was placed in an on-site vision training rehabilitation program and was given home exercises to support her rehabilitation. Her home exercises consisted of Brock string and saccadic eye chart training.<sup>11</sup> The Brock string was primarily used to strengthen eye convergence, to teach the patient to see with both eyes simultaneously, and to minimize suppression of the left eye.<sup>9,16</sup> Horizontal saccadic eye movement was aimed to improve horizontal fixation accuracy. Her on-site vision training program consisted of Dynavision training, sport-specific pitch-and-catch with strobe glasses, and various other training glasses using both eyes and each eye individually.<sup>11,14,15</sup> With regular training and progression of the training, the patient demonstrated benefits. These benefits included improved stereopsis, decreased suppression, better fixation precision of the left eye, improved eye discipline of the left eye, and better coordination of both eyes, along with the ability to enjoy her first 3D movie.

The patient's Dynavision \*A score for both eyes, as well as her home saccade exercise scores, improved over the course of the vision training. The patient's number of hits per minute for the Dynavision \*A score significantly increased from 70 hpm to 101 hpm ( $p \leq 0.001$ ). This reflects improved visual-motor coordination and peripheral visual awareness. The patient's at-home exercises also significantly improved, from a weekly average of 33.4±1.4 cpm for both eyes, 34.1±1.6 cpm for the right eye, and 33.0±1.8 cpm for the left eye to 72.5±0.5 cpm for both eyes, 71±0.10 cpm for the right eye, and 72.0±1.0 cpm for the left eye ( $p \leq 0.001$ ; Figure 1). This significant increase reflects the patient's ability to improve in efficiently and smoothly moving her eyes from target to target with greater speed. It also shows good ocular motor symmetry for individual eyes and both eyes together.

Although her visual acuity and prescription remained the same (20/20 for each eye and OD: -1.50+0.50x045, OS: -2.75+2.75x120), better coordination of both eyes was noted. Remarkably, the stereopsis improved and the patient appreciated 3D vision.

Improvement in stereopsis using the Stereo Fly was noted, from 0.00 mm at baseline to 16 mm at week 30 (Figure 4). We have previously seen similar stereopsis improvement in intercollegiate baseball players following vision training.<sup>18</sup> Stereoacuity testing using the Randot test was recorded as 0/10 at week 0. This improved to 3/10 at 6 weeks, 4/10 at 20 weeks, and 6/10 at the completion of the vision training and rehabilitation program (Figure 1). The patient likely improved her stereopsis and stereoacuity by a combination of decreased suppression, improved eye discipline of the left eye, and better coordination of both eyes.

Aside from the improvement in stereopsis, after only seven weeks of the vision training program, the patient was able to see 3D. The misalignment of the patient's eyes resulting from her exotropia ultimately resulted in conflicting input to her brain, which caused increased suppression and an absence of stereoscopic vision. Through vision training, the patient learned how to use both of her eyes simultaneously and was able consciously to change her viewing habits.<sup>6</sup> We believe that through activation of the brainstem and basal forebrain, neuromodulators, including dopamine and serotonin, facilitate and strengthen synaptic changes, which underlie this training effect.<sup>6,10,20</sup> As with any learned change, with consistent practice, the brain's circuitry is able to rewire, resulting in new synaptic circuitry and improved ocular motor performance.

Adduction of the left eye was an area of emphasis, using a version of constraint-induced therapy principles<sup>12,16</sup> by patching the right eye and forcing the left eye to adduct. For example, the Dynavision drills were often done with one eye patched, and the subject was required to adduct her left eye in order to perform the prescribed tasks. Brock string and pitch-and-catch were also done in this way. Therefore, similar muscular performance tasks were achieved by varying the rehabilitation methods.

We note in this report that the initial rehabilitation sessions were cut short due to concern regarding symptoms being evoked. These symptoms were fatigue and decreased adduction of the left eye. Our concern regarding evoking symptoms is two-fold. First, evoking symptoms that make the subject feel unwell come with the risk of decreased compliance. Compliance was maintained with the help of the mother and with requests to document and to report home saccade numbers. These were reported regularly. Many athletes are accustomed to fatigue and operate with the no-pain-no-gain attitude, but with ocular motor performance that involves non-voluntary suppression, we were concerned that fatigue or discomfort could initiate a noci-like reflex. Noci reflexes are often associated with altered or new reflex loops that could lead to worsening of symptoms or diminished performance. Therefore, in the initial training stages, we endeavored to minimize fatigue and discomfort so that the risk of noci reflexes could be avoided.

We do not make sports performance enhancement claims for this patient as this was not the goal of the vision training.<sup>21</sup> However, the patient continued to participate in competitive soccer during the vision training. We do not condone competition of this sort in patients who have poor stereopsis and/or suppression, but the patient came to us as a competitive athlete and continued to participate and perform at a competitive level.

We believe that vision training can be used to treat exotropia and show results of improvement. Improvement and treatment occurred despite years of exotropia with suppression; suppression decreased, stereopsis improved,

and the exotropia was substantially reduced (Figure 4). The patient's mother reported that her daughter occasionally needs to be reminded to "fix her eye," and the eye is voluntarily brought in. The patient did not use prisms during the rehabilitation process.

Certain aspects of the vision training were designed and performed based on strength and conditioning principles. That is, the exercises for the ocular motor training were initiated and performed to improve strength and endurance of those muscles. Therefore, slow and continuous conditioning showed results. Long-term vision training may also be needed to maintain ocular motor condition via an extended vision training program as there is the risk of muscle weakness and atrophy.<sup>22,23</sup> Moving forward, the patient was advised to continue with the home exercises once per week.

## Conclusion

We conclude that vision training can have substantial benefits concerning stereopsis and binocularity. Of note is that ocular motor performance improved to a substantial extent in a 14-year-old post-surgical over-correction. The functional results included improved left eye alignment, diminished exotropia, and good stereopsis.

## Acknowledgements

This work was supported in part by a generous donation from Geraldine (Ginger) Warner to the University of Cincinnati to purchase the Dynavision system. Her support is acknowledged. The authors have no conflicts to report.

## References

1. Serna A, Rogers DL, McGregor ML, Golden RP, et al. Treatment of symptomatic convergence insufficiency with a home-based computer orthoptic exercise program. *J AAPOS* 2011;15(2):140-3.
2. Stine CD, Arterburn MR, Stern NS. Vision and sports: a review of the literature. *J Am Optom Assoc* 1982;53(8):627-33.
3. Helveston EM. Visual training: current status in ophthalmology. *Am J Ophthalmol* 2005;140(5):903-10.
4. Zupan M, Wile A. Eyes on the prize. *Training and Conditioning* 2011 March;21(2):11-5.
5. Abernethy B. Training the visual-perceptual skills of athletes. *Insights from the Study of Motor Expertise. Am J Sports Med* 1996;24(6 Suppl):S89-92.
6. Barry SR. *Fixing My Gaze: A Scientist's Journey into Seeing in Three Dimensions*. New York: Basic, 2009.
7. Richard JM, Parks MM. Intermittent exotropia. Surgical results in different age groups. *Ophthalmology* 1983;90(10):1172-7.
8. Sanfilippo PG, Hammond CJ, Staffieri SE, Kearns LS, et al. Heritability of strabismus: genetic influence is specific to eso-deviation and independent of refractive error. *Twin Res Hum Genet* 2012;15(5):624-30.
9. Wakayama A, Nakada K, Abe K, Matsumoto C, Shimomura Y. Effect of suppression during tropia and phoria on phoria maintenance in intermittent exotropia. *Graefes Arch Clin Exp Ophthalmol* 2013;251(10):2463-9.
10. Clark JF, Colosimo A, Ellis JK, Mangine R, et al. Vision training methods for sports concussion mitigation and management. *J Vis Exp* 2015;(99):e52648.
11. Clark JF, Ellis JK, Bench J, Khoury J, Graman P. High-performance vision training improves batting statistics for University of Cincinnati baseball players. *PLoS One*. 2012;7(1):e29109.

12. Fleet A, Che M, Mackay-Lyons M, Mackenzie D, et al. Examining the use of constraint-induced movement therapy in Canadian neurological occupational and physical therapy. *Physiother Can* 2014;66(1):60-71.
13. Page S, Boe S, Levine P. What are the ‘ingredients’ of modified constraint-induced therapy? An evidence-based review, recipe, and recommendations. *Restorative Neurology & Neuroscience* [serial online] 2013;31(3):299-309. Available from: Academic Search Complete, Ipswich, MA. Accessed November 24, 2014.
14. Kauffman DC, Clark JF, Smith JC. The influence of sport goggles on visual target detection in female intercollegiate athletes. *J Sports Sci* 2015;33(11):1117-23.
15. Vesia M, Esposito J, Prime SL, Klavara P. Correlations of selected psychomotor and visuomotor tests with initial Dynavision performance. *Percept Mot Skills* 2008;107(1):14-20.
16. Scheiman M, Wick B. *Clinical Management of Binocular Vision*. New York: Lippincott, 1994:188-92.
17. Clark JF, Graman P, Ellis JK, Mangine RE, et al. An exploratory study of the potential effects of vision training on concussion incidence in football. *Optom Vis Perf* 2015;3(2):116-25.
18. Clark JF, Graman P, Ellis JK. Depth perception improvement in collegiate baseball players with vision training. *Optom Vis Perf* 2015;3(2):106-15.
19. Clark JF, Middendorf A, Hasselfeld KA, Ellis JK, Divine JG. Aggressive rehabilitation pathway targeting concussion symptoms: illustration with a case study. *Brain Disorders & Therapy* 2014;3:131.
20. Grooms D, Appelbaum G, Onate J. Neuroplasticity following anterior cruciate ligament injury: a framework for visual-motor training approaches in rehabilitation. *J Orthop Sports Phys Ther* 2015;45(5):381-93.
21. Schwab S, Memmert D. The impact of a sports vision training program in youth field hockey players. *J Sports Sci Med* 2012;11:624-31.
22. Peck M. How a movie changed one man’s vision forever. 2014. <http://www.bbc.com/future/story/20120719-awoken-from-a-2d-world>
23. Kirscher DW. Sports vision training procedures. *Optom Clin* 1993;3(1):171-82.

---

*Correspondence regarding this article should be emailed to Joseph F. Clark, PhD, at [joseph.clark@uc.edu](mailto:joseph.clark@uc.edu). All statements are the authors’ personal opinions and may not reflect the opinions of the representative organizations, ACBO or OEPF, Optometry & Visual Performance, or any institution or organization with which the authors may be affiliated. Permission to use reprints of this article must be obtained from the editor. Copyright 2016 Optometric Extension Program Foundation. Online access is available at [www.acbo.org.au](http://www.acbo.org.au), [www.oepf.org](http://www.oepf.org), and [www.ovpjournal.org](http://www.ovpjournal.org).*

Clark JF, Holloway GM, Elgendy-Peeran HT, Ellis JK. Vision training to improve a consecutive exotropia: A case study with a 14-year-old female athlete. *Optom Vis Perf* 2016;4(4):133-8.

---

***The online version of this article contains digital enhancements.***

# “MFBF” Matching Game

The MFBF Matching Game (also known as Red Red Rock Game) was developed as an activity for use in all aspects of vision therapy. The goal of this activity is to serve as a bridge from monocular to binocular activities, improving efficiency of the patient’s use of accommodative and binocular systems. This game offers 7 levels of exercises based on the age and capability of the patient.






[www.oepf.org/MFBF\\_Game](http://www.oepf.org/MFBF_Game)