

Article ▶ “The Day the World Tilted:” A Case Study on Visual Vertigo and Anomalous Spatial Perception

Katie Davis, OD; Illinois College of Optometry, Class of 2014
Charleston, South Carolina

Optometrists Change Lives Writing Competition 2014 Winner

ABSTRACT

Background: In order to maintain balance, input from the vestibular, somatosensory, and visual systems must work together to allow the patient to perform comfortably and to exist in his or her world. Any imbalance leads to a multitude of symptoms, including vertigo or disequilibrium. This paper analyzes a case of a patient suffering from long-standing vertigo and self-reported debilitating visual dysfunction.

Case Report: A 47-year-old female presented with complaints of long-standing dizziness, a feeling of sickness in busy areas like grocery stores, the inability to multitask (including the inability to walk and talk at the same time comfortably), motion sensitivity, and disorientation. Due to her symptoms, the patient was unable to work, drive, or interact in social situations. Visual analysis revealed convergence insufficiency, oculomotor dysfunction, visual-vestibular sensory mismatch, and anomalous spatial perception. Traumatic brain injury testing quantified the patient’s complaints. Completion of a vision therapy program, with an emphasis on dynamic techniques including procedures to rehabilitate accommodative, vergence, and oculomotor insufficiencies, allowed the patient to return to her activities of daily living.

Conclusion: In order to assist in the rehabilitative process, optometrists and other medical professionals must be cognizant of the vital role the visual system plays in regulating balance. Vision therapy must be considered as a treatment option to allow the rehabilitation process to be effective.

Keywords: balance, motion sensitivity, postural control, spatial localization, vestibular dysfunction, vision therapy, visual vertigo

Introduction

One third of all dizziness and vertigo symptoms stem from a vestibular problem.¹ To explain these clinical conditions, the basic anatomy of balance can be described using an input-output model. The vestibular, somatosensory, and visual systems are responsible for providing afferent signals to the brain and producing an efferent response. The vestibular apparatus transmits information from the otoliths, utricle and saccule, and semicircular canals via cranial nerve VIII (vestibulocochlear

nerve) to the vestibular nuclear complex within the brainstem. The utricle and saccule provide information on static equilibrium and linear changes in velocity, while the semicircular canals provide detail about rotational changes in velocity, all in relationship to gravity.² At times, when our body is moving at a constant velocity, the semicircular canals do not provide further information; instead, we must rely on the shifting frames of reference in our visual field, or optic flow.³ The semicircular canals’ orientations mirror the functional actions of

the extra ocular muscles (EOMs), and because of this, communication is directed to the EOMs to maintain foveal fixation on an object moving through space. The vestibulo-ocular reflex (VOR) is responsible for compensatory eye movements, ensuring accurate visual-spatial interpretation of the visual field as the head is moved while following an object of regard.² When the head is stationary, the vestibular organs have a resting firing rate that is equal on both sides. When the head turns in one direction, the impulses increase in the direction of movement and decrease on the opposing side to stabilize gaze during active head movement. Damage to either vestibular apparatus releases conflicting information about movement, causing the sensation of vertigo.⁴

The somatosensory system uses mechanoreceptors embedded in muscles throughout the body to determine how the body is positioned in space. In Skeffington's four-circle model of vision, this is known as anti-gravity. By relating the amount of stretch and compression around a joint, a mental map of where all body parts exist in relation to each other can be compiled.³ This information is carried from the peripheral nervous system through the dorsal root ganglia of the spinal cord to reach the primary somatosensory cortex, and then it can be modified in association centers located throughout the cortex in final motor integration regions.² The motor integration regions are all part of the feedback loop that cross-checks information derived from these sensory systems.

The third part of the model is the visual system, which is responsible for the interpretation of motion of the environment projected on the retina during our movement. This is known as optic flow.⁵ The visual system can be broken down into two simplified streams, dorsal and ventral. The ventral system, also referred to as the focal or parvocellular stream, is related to object identification. The dorsal system, referred to as the ambient or magnocellular stream, originates from predominantly peripheral

retinal fibers and contributes to localization in space, balance, movement, coordination, and posture. These peripheral retinal fibers travel to the midbrain and synapse in the superior colliculus, where they are joined by information from the auditory system via the inferior colliculus, somatosensory input via the spinal cord projections, and retinal ganglion magnocellular cells that did not synapse in the lateral geniculate body. At the superior colliculus, they coordinate to aid in spatial orientation (the relative distances between objects in the visual field and the observer), the ability to discern self-motion from environmental motion, posture, and balance.² There is an additional feedback loop that takes information from the superior colliculus through the optic nerve back to the retina. Although the exact function of this secondary loop is unknown, it is speculated that it may explain how we recognize objects in our field before, optically speaking, we can see them.³ If any of the information from the three systems that regulate balance, compiled at the superior colliculus, is insufficient or incorrect, the feedback to the retina further confounds sensory perception. Malfunctions of any of the sensory systems are responsible for a myriad of clinical conditions.

Visual vertigo (VV) is defined as dizziness caused by total field pattern stimulation, specifically from the magnocellular visual system, causing illusory movement and disequilibrium. The prevailing theory for the etiology of this motion sensitivity is a mismatch between the visual, vestibular, and proprioceptive systems that forces the patient to rely more heavily on visual input in conflict with the other systems.⁶ This visual dependence directs the brain to suppress vestibular and some proprioceptive signals and to rely on the overwhelmed and distorted visual system for balance.⁴ Ocular motility dysfunction exacerbates vestibular dysfunction, and patients may report episodic dizziness, tiredness, imbalances, and anxiety in addition to complaints of diplopia, problems reading,

or difficulty focusing for long periods of time.² When the VOR is damaged, movement of nearby objects or an overly stimulating visual field can be perceived as self-movement. The sensation of false self-movement can be provoked during sensations of passive movement, like when riding in a car, while watching trains pass, or during perceived environmental motion while a person is standing still.¹ These patients will react to perceived optic flow with large physical posture changes and perceptual responses to the distressing visual environment.⁶ Clinically, patients will demonstrate perceptual difficulties with figure-ground discrimination, visual sequencing, visual closure, and speed and span of visual recognition.² Aniseikonia and horizontal or vertical ocular misalignments all confound visual dependence on the vestibular system.⁷ In order to have accurate body movements, correct proprioceptive information regarding individual body orientation (egocentric localization) and information regarding relative positions of objects to each other (allocentric localization) must be interpreted correctly.⁸ Sensory information derived from egocentric and allocentric localization in neurologically normal individuals occasionally may manifest slight misalignments that can be accurately adjusted.⁸ Patients suffering from VV and other anomalous spatial perception disorders are not able to make accurate spatial localization and postural adjustments to conflicting sensory inputs and therefore are highly symptomatic.

Case Report

A 47-year-old Caucasian female presented to the clinic with complaints of significant visual distortions, disorientation, balance issues, and sensitivity to movement, crowds, and lights. She described an incident five years prior when she turned her head to speak to someone and “the whole world tilted to the left.” She reported, “The tilting continued for a few weeks and then subsided, but I was left feeling off balance and distorted ... as if I was falling, even

Rx: None	Always	Near Only	Far Only	Bifocals
Sim. Percept.	Pig	Dog	Dog Pig	Dog Pig
Fusion	⊙ ●	⊙ ●	⊙ ● ④ ③	④ ③ ⊙ ●
Stereopsis—DB	1 2 3 4 5 6 7 8 9 10 11		⑫	
Multi-Stereo				
Lat. Phoria		1 2 3 4 5 6 7	8 9 10	⑪ 12 13 14 15
Vert. Phoria		○	⊙	○
Hand & Eye Coordination		Landings Inaccurate Suppression Pointer	Accurate Neg.	O.D. O.S. Leads Numbers
Visual Discrimination	O.D. 1 2 3 4 5 6 7 8 O.S. 1 2 3 4 5 6 7 8		9 ⑩ 9 ⑩	04-10
Cent. Suppression	1—	O.S. Sup.	u/Neg	O.D. Sup.—1
Fusion	⊙ ●	⊙ ●	⊙ ● ④ ③	④ ③ ⊙ ●
Lat. Phoria		2 3	4 5 6	7 8 9 10 11 12
Visual Discrimination	O.D. 7 8 9 10 11 12 13 14 O.S. 7 8 9 10 11 12 13 14		15 16 17 18 19 20 21 22 15 16 ⑰ 18 19 20 21 22	
	O.U. 7 8 9 10 11 12 13 14		15 ⑱ 18 19 20 21 22	

Figure 1. Keystone Telebinocular Skills

if I was sitting down.” She was forced to “give up working, driving, and most social activities.” She described a lack of depth perception and a near-total inability to perform her activities of daily living. After seeing many specialists and undergoing four unsuccessful attempts with vestibular therapy, she was told that she would have to live with her condition. She was being monitored by a cardiologist for an arrhythmia and did not take any medications; all other medical history was unremarkable.

At the initial comprehensive eye examination, entering visual acuities through her habitual correction (OD: -1.00 DS, OS: pl-0.50x074) were 20/20 OD and 20/30 OS. Keystone Telebinocular visual skill testing revealed her visual discrimination skills at distance under monocular conditions to be unequal but improved somewhat under binocular conditions. All other distance testing was unremarkable. Keystone Telebinocular near testing demonstrated an inability to achieve fusion and insufficient convergence on lateral phoria testing. Visual discrimination was reduced under monocular conditions and improved moderately under binocular conditions (Figure 1). During chairside vision analysis testing, the EOM evaluation demonstrated abnormal head movements and

in general was difficult to assess as the patient became very dizzy and nauseated and reported feeling “very unbalanced” with small eye movements. While sitting, pursuits were smooth and saccades were jerky. Eye movements to the right were easier than to the left with more head movement to the left. While standing, a change in direction during pursuits would cause her nearly to fall over. Standing saccades were very unsteady; after a few tests, she began to lean forwards and backwards and requested to stop. Stereopsis using Wirt circles was 200 seconds of arc, and she described diplopia with the Worth 4 Dot. Through an updated prescription, OD: -0.75-0.25x005, OS: +0.75-0.25x145 (7B), acuity improved to 20/20 OD and 20/20 OS. In-phoropter testing revealed 13Δ exophoria at near (13B), binocular crossed cylinder of +2.00 (14B), and an unchanged near posture of 13Δ (15B). Base out vergences were x/22/14 (16), and base in vergences were x/18/16 (17). NRA/PRA around 14B were -1.00/+1.50 (20, 21). Visual field screening revealed no losses.

A traumatic brain injury (TBI) examination was performed. The patient’s ambulation was unsteady, and she made jerky head movements whenever she perceived movement near her. Throughout the testing, her head was tilted to the left, and her right hand had a near constant tremor. While testing real space stereopsis using the quoits vectogram, she could not tolerate base out and would lean to the left while testing base in. She reported that the quoit moved side to side throughout all testing, and any sudden movement made her nauseated. During Brock string testing, the patient reported seeing an ‘X’ with occasional suppression. She reported being most comfortable fixating on a bead at three feet, and she noted that one string was higher than the other. The patient did not demonstrate visual neglect or overt visual midline shift. The Romberg, Tandem Walking, and Fukuda tests demonstrated overall instability. Using 15Δ of yoked prism, we asked her to determine whether any of the lenses subjectively improved

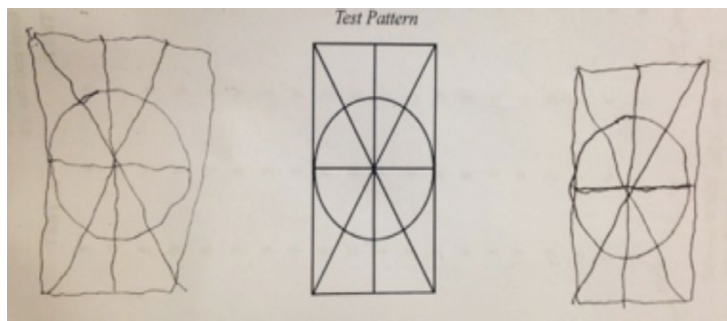


Figure 2. Cheirosopic Tracing by the patient during TBI examination.

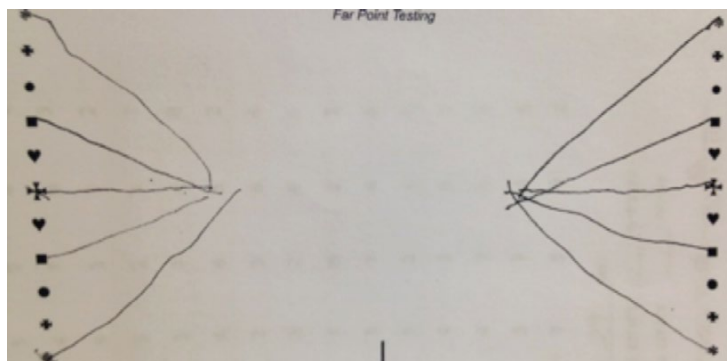


Figure 3. Van Orden Star by the patient during TBI examination.

her postural stability. Base down prism felt very comfortable and improved her stability while seated. However, she reported that base right prism in particular was very disturbing. Visagraph testing showed 70 fixations per 100 words with the left eye, 68 fixations per 100 words with the right eye (grade norm 77, 14 regressions per 100 words in the right eye (grade norm 11 <5), and 9 regressions per 100 words with the left eye. Average span of recognition and duration of fixation were within normal limits. Directional Attack Difficulty was 20% (grade norm 14%, goal under 9%), and reading comprehension was 80%. Spatial localization testing with the cheiroscope, seen in Figure 2, revealed distortions consistent with aniseikonia and subtle ocular misalignment. General observations included her inaccurate depth judgment, inaccurate eye-hand coordination, limited peripheral awareness, and general fatigue with visual tasks. Oculomotor dysfunction, binocular vision disorder, inconsistent fusion with defective stereopsis, visual vertigo, and spatial localization dysfunction were identified and treated with vision therapy.

Therapy sought to stabilize fixation and ocular motility, develop a flexible binocular

vision system, enhance peripheral awareness, develop accurate spatial localization, diminish optic over-flow, and encourage visually related cognitive processing speed, memory, and flexibility. The patient hoped to be able to read comfortably again, prevent walking into door jambs, see the curb better when walking, have improved energy levels, and not to be disoriented in an active visual environment like the grocery store. During therapy, it was noted that she often exhibited characteristics of an autistic child with sensory dysfunction. She was extremely sensitive to touch, sound, and lights; liked to hold a specific bean bag while she performed therapy activities; and reported feeling better while wearing a weighted vest. These signs prompted a referral to an occupational therapist to supplement her work in vision therapy.

Techniques that eventually would allow for voluntary control of the visual process were chosen, specifically emphasizing repetitive tasks with feedback during performance and incorporation of multi-sensory integration.⁹ Her individualized therapy program began in the monocular phase to equalize basic visual skills between the two eyes. She was seated in an area with uncluttered backgrounds in order to limit the effects of over-stimulating optic flow. Eye-hand and motor techniques were emphasized to aid in the integration of tracking and locating to match motor with sensory interpretation. Orientation therapy with yoked prism to generate a controlled sensory disruption was included in the early phases. The patient was able to tolerate small visual changes with yoked prism activities beginning with two prism diopters while she remained stationary. Eventually, techniques were transitioned to an unmoving fixation with physical changes: for example, swing activities. Binasal occlusion during certain therapy techniques encouraged the use of peripheral vision. Other peripheral awareness activities were incorporated to enhance the integration of central and

peripheral awareness. Visual perception skills were incorporated to encourage visual memory, visual closure, figure-ground discrimination, and spatial relationships.

As monocular skills equalized, monocular-in-a-binocular-field techniques were used while transitioning into biocular and binocular therapy. Vergence ranges improved to allow dynamic functions. Accommodative flexibility was developed. Techniques were once again first attempted in uncluttered areas while seated until loading was possible using the balance board and metronome. Techniques emphasizing vestibular integration were incorporated. Look-touch techniques were used to encourage peripheral awareness and eye-motor fine control, as well as auditory, motor, and visual integration as the levels progressed. Peripheral awareness training continued as well as yoked prism activities of increasing magnitude as she was able to endure more demanding tasks.

In the early stages of therapy, it was noted that fusion locks would relieve her symptoms of dizziness and discomfort. Therefore, whenever a particular technique triggered her symptoms, typically when loaded with additional stimuli recruiting sensory systems, an activity requiring red/green glasses or polarized lenses would relieve her symptoms. Generally speaking, all therapy sessions ended with fusion games or something similar to ensure that she experienced minimal discomfort after her session. Home vision therapy matched in-office phasing with synchronized loading. Initial techniques included eye movement control activities, balance activities, circle fill-in, near-far Hart chart, pencil pushups, and pointer in the straw. As she progressed, higher-level activities were incorporated such as fusion walking, ball scrambles, and the Randolph shuffle. Various Marsden ball activities, vestibular bean bag activities, eccentric circles, and convergence stimulators were employed. She enjoyed reading with the red/green bars and installed a swing at home.

After 68 therapy sessions, the patient reported, "The world is BIG!" She appreciated an improvement in depth perception and general function. She was now able to return to work and expanded her social activities. At her final visual analysis exam, EOMs were full, and she achieved 20 seconds of arc via the Wirt circles and fusion via Worth 4 Dot. Keystone Telebinocular visual skill testing demonstrated improved fusion, normalized phoric posture, and equalized monocular visual discrimination at all distances. Her final distance corrective lenses were plano with four prism diopters base up OU and a pair of near single vision lenses without prism. She graduated from therapy, has maintained regular follow-up, and continues maintenance therapy at home.

Discussion

Vision rehabilitation programs are in a unique position to help patients with visual, vestibular, and somato-sensory mismatches. High level (and expected) visual function is a combination of automatic processes and voluntary, complex visual decision-making. Automatic or bottom-up processing responds to visual stimuli in the visual space from sensory receptors. Structural damage from ocular pathology can affect this level of visual processing. As the eyes are unsure where to look and visual information defining the location of objects in the patient's visual space is unclear, anomalous spatial perception occurs. Complex visual decision-making, or top-down processing, is a learned system built upon experience. Generally speaking, the dorsal stream is directly involved in top-down processing and is particularly susceptible to axonal injury from brain trauma or disruption.⁹ In this patient's case, both systems were idiopathically disrupted. Automatic processes controlling eye movements were no longer accurate, and disruption of higher-order visual processes allowed bottom-up processing to become more pronounced and disruptive. Therapy mimics the natural evolution of the

sensory systems and allows basic functions to become reorganized and complex visual tasks to be taught to the patient again.

Many changes to visual perception are correlated to symptoms following an acquired brain injury and visual vertigo. VV can be correlated with problems with speed of information processing, visual-motor integration, visual-auditory integration, visual memory, visual closure, changes to comprehension of spatial relationships, and figure-ground discrimination. For example, a 'figure' is part of the sensory information to which a person is attending or recognizes. The 'ground' is everything to which a person is not attending but is being registered by the subconscious. If a stable ground is not perceivable, an identifiable figure is not able to emerge, as it will not be positioned relative to any particular object in the field.³ The patient's compensation of visual dependence from the overall sensory mismatch and spatial distortion due to poorly functioning eye movements overwhelms the system, prevents attention to only the necessary details, and distorts interpretation of optic flow. Motion hyper-sensitivity ensues. The visual information processing skills are part of top-down processing, indicating that decision making is being interrupted at some level; therefore, these skills are very amenable to rehabilitation.¹⁰

Cheirosopic tracing gives insight into changes in spatial relationships. The stereoscope is constructed in such a way that when the patient is asked to trace the image, one eye views the image and the other views the image being traced. After the first image is completed, the drawing is shifted, and the pencil is placed in the other hand to result in two drawings that can be compared. Comparisons demonstrate shifts or relative rotations indicating the phoric posture of the patient at the time of testing. Size differences demonstrating aniseikonia can also be observed.¹⁰ The Van Orden (VO) Star also objectively illustrates the balance between central and peripheral function and

demonstrates spatial perceptual distortions indicated by the locations and arrangement of the apices of the lines. If the patient is able to see both columns concurrently, with a pencil in each hand, they are asked to draw a line from the center cross on both sides and to stop when the two lines appear to connect. The left hand is then moved to the top left symbol, and the right hand is moved to the bottom right symbol. The activity is continued until the star is completed.¹¹ The apex on the left side of the patient's VO star (Figure 2) was half a centimeter shorter than the right. The size difference indicates discrepancies in the focal and ambient system relationship that, for this patient, were manifested in physical/functional ill performance. The subtle difference can be interpreted as a rotation around the vertical axis representing a postural shift along the mid-body axis.¹¹ The patient perceived the frontal plane closer on the right side and further away on the left side. This is also demonstrated by the shift into the upper right quadrant noted during cheirosopic tracing and her left head tilt with the tendency to lean to the left during stereo-vergence testing, all in an attempt to stabilize her spatial field. The apex of the patient's VO star was also less organized on the left side, indicating a functional space that is distorted with intermittent central suppression. These findings all relate to the patient's perceived severe spatial disorganization and distress within her world.¹¹ The perception of an enlarged image on the left side seen with the cheirosopic tracing is related to spatial warpage, as the enlarged image is either a result of a frontal shift as an attempt to compensate for an image that appears further away or a cause of the shift, where the system tilts the right-hand plane closer to attempt to equalize the aniseikonia.

Vestibular and neurological therapies typically recommend visual motor desensitization emphasizing repeated optokinetic exercises to alleviate symptoms.⁶ Optometric vision therapy strives to reinstate a stable

binocular vision system with an emphasis on dynamic and multi-sensory function. Techniques to strengthen fusion and bi-foveal fixation, encourage flexible accommodative and vergence systems, and restore spatial egocentric and allocentric localization are utilized. Dynamic techniques integrating multiple sensory systems concurrent with typical accommodative, vergence, or oculomotor exercises are part of routine rehabilitation. Yoked prism exercises help the three main sensory systems communicate more effectively and accurately. Encouraging the use of vestibulo-proprioceptive cues to tolerate disorienting visual stimuli aids the patient in transitioning from visual postural control to normal proprioceptive postural control.¹² Visual motor, auditory visual, and visual vestibular integration are paramount to achieving clear, comfortable binocular vision.⁷ As these systems are rehabilitated, the patient's temporal-spatial world stabilizes, and the patient regains the ability to attend to only the relevant objects in the sensory field and regains control of their visual world.

Conclusion

Neurologically, the vestibular, somatosensory, and visual systems work synergistically via feedback loops to verify sensory information. This characteristic lends itself to a plastic system that is malleable and able to be rehabilitated. Because vertigo or dizziness is a catch-all term for a variety of sensory dysfunctions, a careful case history is important to ensure that the patient receives the proper medical care. A multi-disciplinary approach to rehabilitation should be coordinated with neurology, audiology, physical therapy, occupational therapy, and chiropractic care to aid the patient in maximizing their functional potential. The optometrist's unique position to aid in fluent visual perceptual processing and motor planning in conjunction with other rehabilitative techniques is important to holistic care.

References

1. Berliner JM [Homepage on the internet]. Visual Vertigo/ Motion Sensitivity. American Physical Therapy Association, Section on Neurology. 10 Apr 2014. Available from: <http://bit.ly/1UnoFI7>
2. McGovern MJ, Kapoor N. Vision and Balance: An Optometric Survival Guide. American Academy of Optometry Meeting 2012, Phoenix, AZ. 10 Apr 2014. <http://bit.ly/1XSI6gH>
3. Harris P. What is Vision & the Space World. Behavioral Vision Care. Behavioral Vision Project;nd:1-18, 1-24. <http://bit.ly/1i3a5cq>
4. Vestibular Disorders Association. Vision Challenges with Vestibular Disorders. www.vestibular.org. 10 Apr 2014. Available from: <http://bit.ly/1lyZxYf>
5. Li L. Optic Flow. University of Hong Kong;nd:Web. 11 Apr 2014. Available from: <http://bit.ly/1LFtGtk>
6. Guerraz M. Visual vertigo: Symptom assessment, spatial orientation and postural control. *Brain* 2001;124:1646-56. <http://bit.ly/1FBhuWb>
7. Mejia GA. Vision & balance: The optometrist's role in managing patients with dizziness and vestibular dysfunction. *J Behav Optom* 2008;19:97-102. <http://bit.ly/1O5kPoo>
8. Houston KE. Measuring visual midline shift syndrome and disorders of spatial localization: A literature review and a new clinical protocol. *J Behav Optom* 2010;21:87-93. <http://bit.ly/1g8sK4I>
9. Chang A, Cohen A, Kapoor N. Top-down visual framework for optometric vision therapy for those with traumatic brain injury. *J Optom Vis Perform* 2013;1:48-53. <http://bit.ly/1iC0hqG>
10. Suter PS, Lisa HH. Vision Rehabilitation: Multidisciplinary Care of the Patient Following Brain Injury. Boca Raton, FL: CRC, Taylor & Francis Group, 2011:336-40. <http://bit.ly/1K07kjN>
11. Kaplan M, Lydon CM. The Van Orden star: A window into personal space. *Optom Vis Devel* 2002;33:21-7. <http://bit.ly/1L6chf1>
12. Bartal AM. Visual vertigo syndrome (Journal Article Review). The VisionHelp Blog. 10 Dec 2010. Web. Last accessed 10 Apr 2014. Available from: <http://bit.ly/1JGQ726>

Correspondence regarding this article should be emailed to Katie Davis, OD, at klored@gmail.com. All statements are the author's personal opinions and may not reflect the opinions of the representative organizations, ACBO or OEPP, Optometry & Visual Performance, or any institution or organization with which the author may be affiliated. Permission to use reprints of this article must be obtained from the editor. Copyright 2015 Optometric Extension Program Foundation. Online access is available at www.acbo.org.au, www.oepf.org, and www.ovpjournal.org.

Davis K. "The day the world tilted:" A case study on visual vertigo and anomalous spatial perception. *Optom Vis Perf* 2015;3(BSK):18-25.
