

# Article ▶ Pediatric Idiopathic Intracranial Hypertension: A Case Report

Divya Nandwani, OD, State University of New York College of Optometry, New York, New York

Marilyn Vricella, OD, State University of New York College of Optometry, New York, New York

Scott Richter, OD, State University of New York College of Optometry, New York, New York

## ABSTRACT

**Background:** Idiopathic intracranial hypertension (IIH) presents differently in prepubertal children as compared to postpubertal children and adults. In adults, IIH is most common in obese women of child-bearing age. However, when occurring in prepubertal children, IIH has been shown to have no predilection for gender and does not correlate with obesity. This case report exemplifies the rare occurrence of IIH in a pediatric patient.

**Case Report:** A five-year-old Hispanic female patient was seen at the University Eye Center for a longstanding hypotropia secondary to a likely congenital fourth nerve palsy with an exotropia component. After a strabismus surgery and a series of follow-up visits, bilateral swollen optic nerves were observed, and a prompt referral to the emergency room was made. Consequently, she was diagnosed with IIH. A treatment regimen of acetazolamide was initiated with subsequent improvement of the clinical presentation of increased intracranial pressure, confirmed by the reduction of swelling of her optic nerves.

**Conclusions:** Bilateral swelling of the optic nerves can be an emergency, especially in children. It is important urgently to rule out causes for increased intracranial pressure. If treatment is significantly delayed, or if no treatment is given to a patient with this condition, loss of visual function may occur. In addition to reporting a rare circumstance of pediatric idiopathic intracranial hypertension, this case report serves to remind eye care practitioners of the importance of monitoring the ocular health of patients closely, even in young, healthy children.

**Key Words:** acetazolamide, cerebrospinal fluid pressure, headache, optic nerve, pediatric idiopathic intracranial hypertension, strabismus

## Introduction

Idiopathic intracranial hypertension (IIH) is a condition that has the associated sign of increased intracranial pressure. It is characterized by elevated cerebrospinal fluid (CSF) pressure with normal CSF composition; no hydrocephalus, mass, structural or vascular lesion on neuroimaging; and no identifiable etiology.<sup>1</sup> IIH has an overall incidence of 1 in every 100,000. Due to the chronic nature of IIH, the prevalence in adults is even greater.<sup>2</sup> IIH is known to be most common in young obese women, in which the incidence can be as high as 19.3 in 100,000.<sup>3</sup> While IIH in pediatric patients is less common, it has the same potential for vision loss as the adult form.<sup>4</sup> It has been noted that IIH may have a different presentation and etiology in children and that the onset of puberty is the indicator that separates adult from pediatric IIH.<sup>4,5</sup>

IIH is idiopathic by definition and is a diagnosis of exclusion; therefore, it is always important to rule out an identifiable cause of increased intracranial pressure. The modified Dandy criteria are currently used to aid in the diagnosis of IIH, which include: 1) a normal cranial computed tomography (CT) scan and/or magnetic resonance imaging (MRI), confirming the absence of a mass lesion or hydrocephalus; 2) elevated cerebrospinal fluid (CSF) pressure with normal fluid content; and 3) normal

results on a neurologic examination with the exception of papilledema, visual disturbances, or sixth nerve palsy.<sup>6</sup>

This report describes the diagnosis and treatment of a five-year-old female who was originally being followed for a longstanding congenital fourth nerve palsy and subsequently developed pediatric IIH. It is essential for eye care practitioners to monitor ocular health thoroughly even in young, seemingly healthy children because in conditions involving bilateral swollen optic nerves, early diagnosis and treatment is imperative to prevent vision loss and to rule out life-threatening causes.

## Case Report

A five-year-old Hispanic female presented to the University Eye Center in the summer of 2012 for her first eye exam. Her mother's main complaint was that the patient's left eye turned up and out about 90% of the time since the age of two years. The mother reported that the patient also had an associated right head turn. The remaining visual, ocular, medical, and birth history was unremarkable. The patient was in good health, had no current medications, and did not have any history of neurological disease or trauma. Uncorrected visual acuities were 20/25<sup>+2</sup> in each eye taken with the distance Allen chart and 20/20 in each eye with the near Allen chart. Her dry retinoscopy was

+0.50-0.75x180 in the right eye and plano-0.50x180 in the left eye. Upon observation, the patient had a head turn down and to the right. Distance cover test revealed a 25 prism diopter constant right hypotropia and a 6 prism diopter constant right exotropia. Near cover testing revealed a greater than 25 prism diopter constant right hypotropia and a 10 prism diopter constant right exotropia. In left gaze, the vertical deviation significantly decreased to a phoria only, correlating with the patient's head turn. Examination of versions revealed decreased elevation of the right eye in upgaze and left inferior oblique over-action with a left superior oblique under-action; ductions showed no restrictions in either eye. She was unable to demonstrate stereoacuity with the Random Dot Stereogram. Her pupils, confrontation visual fields, refraction, and biomicroscopy were unremarkable. Intraocular pressures were 12 mmHg in the right eye and 11 mmHg in the left eye at 10:00 am taken with a non-contact tonometer. Internal ocular health evaluation with dilation revealed C/D ratios of 0.40 round in each eye, with pink, distinct, and healthy optic nerve heads. Her retinal vasculature and macula were normal in each eye, and no abnormalities were seen in the peripheral retina of either eye. The patient was not given any optical correction and was referred for a strabismus consultation.

The pediatric ophthalmological consultation diagnosed a likely congenital left superior oblique palsy with compensating head turn and an exotropia component. One month later, a left inferior oblique recession surgery was performed by an outside ophthalmologist.

The patient returned the following month for a re-evaluation of the strabismus status-post surgery. Her mother reported that the surgery had significantly helped in the alignment of the eyes, with decreased frequency of the eye turn and decreased magnitude of the head turn. Uncorrected visual acuity was essentially stable at 20/25<sup>+</sup> in each eye at distance and 20/20 in each eye at near with HOTV matching. Motilities were full with no restrictions. Distance cover test revealed an 8 prism diopter constant right hypotropia and a 14 prism diopter constant right exotropia. Near cover test revealed a 4 prism diopter constant right hypotropia and a 4 prism diopter right exotropia. Upon observation, the patient's head turn to the right was still present but to a lesser degree when compared to the previous visit. As expected, she was still unable to demonstrate stereoacuity in primary gaze or left gaze without prism compensation. Her pupils, confrontation visual fields, and refraction remained unremarkable. Pink and distinct optic nerve heads were observed without dilation, with C/D ratios of 0.25 round in each eye, a decreased cup-to-disc ratio from what was previously recorded. Her retinal vasculature and macula areas were normal in each eye. At this visit, no optical correction was given. Due to the residual strabismus status-post strabismus surgery, the patient was referred for a strabismus vision therapy evaluation with a guarded prognosis.

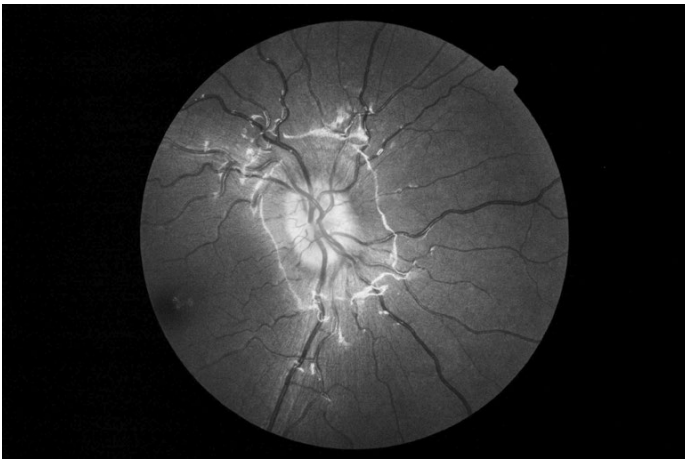
The patient presented for a strabismus vision therapy evaluation one month later. Distance and near visual

**Table 1: Near cover test findings in the nine positions of gaze, quantified by alternating cover test**

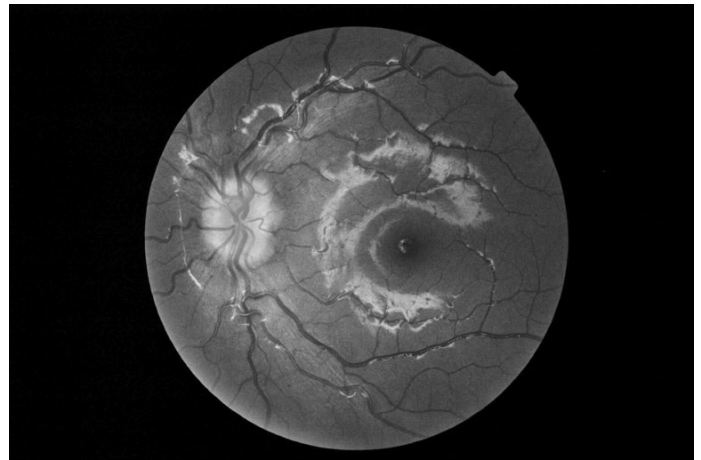
	Right-gaze	Primary	Left-gaze
Upgaze	6 <sup>Δ</sup> left hyper 4-5 <sup>Δ</sup> exo	5-6 <sup>Δ</sup> left hyper 8-10 <sup>Δ</sup> exo	4-5 <sup>Δ</sup> left hyper 4-5 <sup>Δ</sup> exo
Primary	14-16 <sup>Δ</sup> left hyper 2-4 <sup>Δ</sup> exo	6-8 <sup>Δ</sup> left hyper 6-8 <sup>Δ</sup> exo	2 <sup>Δ</sup> left hyper No exo component
Downgaze	6 <sup>Δ</sup> left hyper 2-4 <sup>Δ</sup> exo	5-6 <sup>Δ</sup> left hyper 2 <sup>Δ</sup> exo	2 <sup>Δ</sup> left hyper 4-5 <sup>Δ</sup> exo
Right Head Tilt	N/A	decreased left hyper	N/A
Left Head Tilt	N/A	increased left hyper	N/A

acuity were stable. Examination of versions showed no muscle restrictions and a V-pattern exo posture. Pursuits and saccades were normal. Distance cover test revealed an 8-10 prism diopter constant alternating right hypotropia/left hypertropia and a 10 prism diopter constant alternating exotropia with left eye fixation preference. Near cover test revealed a 6-8 prism diopter constant alternating right hypotropia/left hypertropia and a 6-8 prism diopter constant alternating exotropia with left eye fixation preference. Table 1 shows the cover test findings at near in the nine positions of gaze, where left gaze remained the field with the lowest magnitude of strabismus. The patient's vertical deviation became largest with a left head tilt. These findings were consistent with a left superior oblique palsy. She was still unable to demonstrate stereoacuity. Worth 4-dot testing showed alternate suppression at all distances with left eye preference. Her accommodative amplitudes were mildly reduced with the pull-away method, and her monocular accommodative facilities were normal. Due to her small residual head turn and poor potential for binocularity, vision therapy was not recommended at this time. She was asked to return if symptoms of asthenopia or difficulty reading occurred. She was otherwise to follow up in six months for a strabismus re-evaluation in the Vision Therapy clinic.

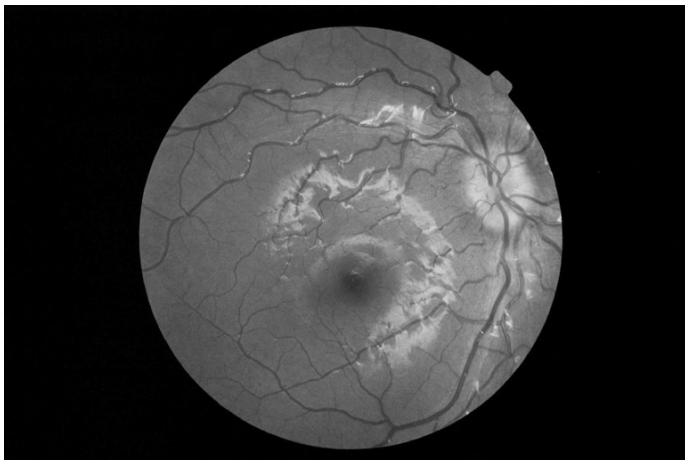
The patient then presented for another follow-up visit one month later. The history was not significant save for the mother's report that the patient had come off the school bus crying due to a severe headache 3 to 4 days prior to the visit. There was no history of new trauma or another antecedent event. The headache resolved in 30 minutes with acetaminophen, and there were no recurrences. The patient denied any headaches at the time of examination and was observed to be running and jumping around in the hallway without apparent distress. Unaided distance visual acuities were 20/25 single letter in each eye with the HOTV chart. Near visual acuities were 20/20 in each eye with the HOTV chart. Motilities were full with a V-pattern exo. Distance cover test revealed a 10 prism diopter constant alternating right hypotropia/left hypertropia and a 4 prism diopter constant alternating exotropia with left eye fixation preference. Near cover test revealed a 6-8 prism



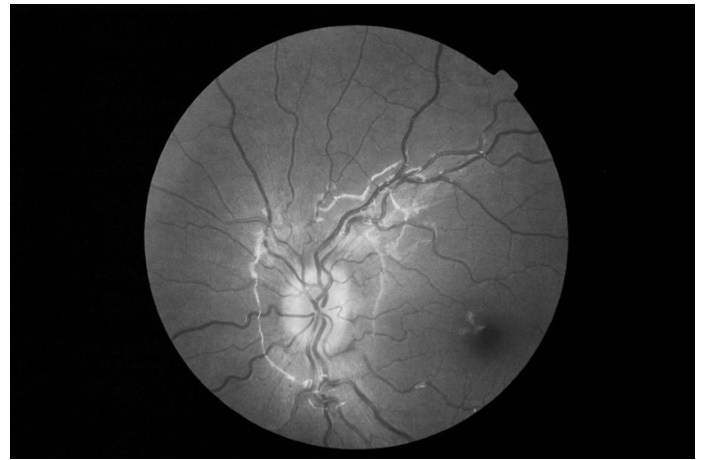**Figure 1.** Right eye when the patient first presented with bilateral swollen optic nerves.



**Figure 2.** Left eye when the patient first presented with bilateral swollen optic nerves.



**Figure 3.** Right eye with resolving papilledema at the two-month follow-up.



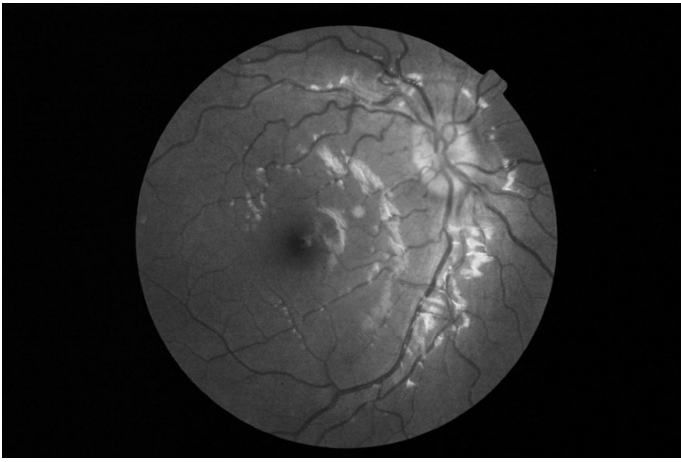
**Figure 4.** Left eye with resolving papilledema at the two-month follow-up.

diopter constant alternating right hypotropia/left hypertropia and an 8-10 prism diopter constant alternating exotropia with left eye fixation preference. Her pupils, confrontation visual fields, refraction, and biomicroscopy were unremarkable. Digital intraocular pressures were soft and equal in each eye. Upon dilated fundus examination, the C/D ratios were reported as 0.10 round with elevated, blurred disc margins 360 degrees in each eye. This was a marked difference from the last dilated view four months prior and the last undilated view two months prior. Both optic nerve heads also appeared lobulated in each eye (Figures 1 and 2). Spontaneous venous pulsation was not observed at this visit. There were no associated hemorrhages, venous dilation, or Paton's folds in either eye. The retinal blood vessels and macular areas were normal in each eye. No abnormalities were seen in the peripheral retina in either eye. B-scan ultrasonography was performed to help rule out the unlikely possibility of optic nerve head drusen; the findings showed hyper-reflective material at the optic nerve head in each eye that disappeared when the gain was lowered, which is not typical of optic nerve head drusen. As a result, the B-scan findings were inconclusive. The retina was flat and intact in each eye. Due to the optic nerve edema and history of headache, the patient was sent to the emergency room immediately with a letter describing her condition and

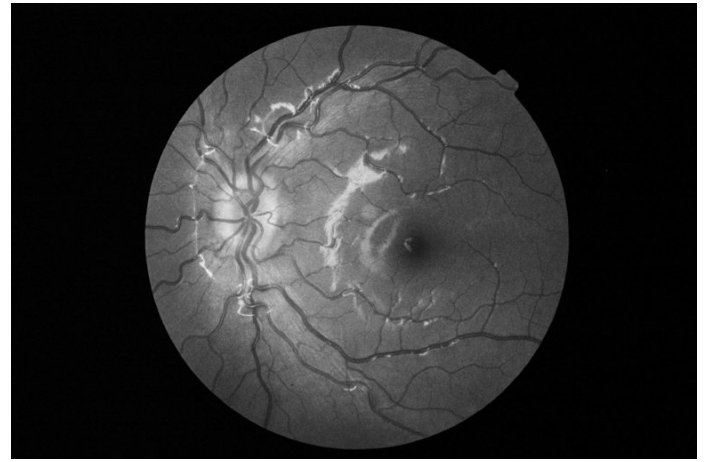suggesting an MRI to rule out increased intracranial pressure and/or any systemic or intracranial abnormalities.

The patient was admitted to the hospital and was subsequently followed by a neurologist. According to the neurological records, an MRI of the brain and orbits with and without contrast did not show any hydrocephalus or mass lesions. Bloodwork, including a complete blood count (CBC) with differential and a lipid panel, was normal with the exception of elevated LDL cholesterol levels. Height (115.2 cm) and weight (22.7 kg) were unremarkable for the patient's age. The patient had a lumbar puncture under sedation with a high opening pressure of 280 mm H<sub>2</sub>O and normal cellular constituents. The patient was started on acetazolamide (Diamox) 250 mg po BID and denied side effects. The neurologist confirmed the diagnosis of IIH.

The patient returned to the University Eye Center two months after her last visit for a follow-up to monitor her papilledema. The patient's mother reported that there had not been any recurrences of headaches since starting the acetazolamide. Unaided distance visual acuities were 20/25 in the right eye and 20/25 in the left eye with the Snellen chart using single letter viewing. Near visual acuities were 20/25 in each eye. Motilities showed no restrictions. Distance and near cover tests were unchanged from the prior exam. Pupils and



**Figure 5.** Right eye with resolving papilledema at the four-month follow-up.



**Figure 6.** Left eye with resolving papilledema at the four-month follow-up.

confrontation visual fields were unremarkable. Monocular color vision was normal with the Hardy Rand and Rittler (HRR) test. Automated visual field testing was deferred due to the patient's young age and inability to perform the test reliably. Dilated fundus examination found C/D ratios of 0.15 with mild disc edema 360° in each eye, which was improved from the previous visit (Figures 3 and 4). A positive spontaneous venous pulsation was now noted in each eye, and no hemorrhages or Paton's folds were noted in either eye. Retinal blood vessels, macula, and peripheral retina were all normal. The diagnosis at this time was resolving papilledema secondary to IIH. It was recommended that she continue use of the medication as prescribed by her neurologist, and she was asked to return to the University Eye Center in six to eight weeks for a follow-up visit.

At the next follow-up visit another two months later, the patient's mother reported that the patient had a reduced appetite, an expected side effect of acetazolamide, but she never complained of stomach pain or headaches. The mother stated that the neurologist had recently decided to decrease the patient's dosage of acetazolamide due to the resolving condition. Uncorrected distance visual acuities were 20/25 in each eye with single letter viewing of the Snellen chart. Cover test, pupils, confrontation visual fields, versions, and biomicroscopy were stable. Upon dilation, the C/D ratios were noted to be 0.25 in each eye, with resolving disc edema, worse nasally than temporally (Figures 5 and 6). There was a positive spontaneous venous pulsation in each eye. The retinal blood vessels, macula, and periphery were normal in each eye. At the following two-month follow-up visit, her visual acuities, cover test findings, and color vision findings were stable. Her optic nerves still had residual edema superior-nasally in both eyes. The patient was scheduled to return another two months later for continued management of her resolving papilledema secondary to IIH but was lost to follow-up.

## Discussion:

This case illustrates the rare occurrence of pediatric IIH in a healthy five-year-old Hispanic female. Pediatric IIH,

which is classified as IIH that occurs before the onset of puberty, differs from adult IIH in etiology and presentation. Because the age at which puberty arises varies greatly, it has been suggested by pediatric medical specialists to use the development of secondary sexual characteristics to identify the onset of puberty.<sup>4,5</sup> These secondary characteristics include menstruation, pubic hair development, and breast or testicular development. In practice, the presence of these characteristics can be confirmed by history from the parents. Unlike adult IIH, which is most common in young, obese women, there have been several reports that prepubertal IIH affects boys and girls similarly without regard to obesity.<sup>4,7</sup> This case is consistent with these characteristics in that our patient was not obese.

The most common presenting sign of IIH in pediatric patients is a headache; however, symptoms such as nausea, vomiting, stiff neck, lethargy, poor appetite, and somnolence may also occur.<sup>2,4,7</sup> Diplopia and strabismus are also common presenting symptoms, with the most common being an acute unilateral or bilateral sixth nerve palsy.<sup>8</sup> Acute fourth nerve palsies have also been shown to occur with pediatric IIH, and these cranial nerve deficits are reversible with normalization of intracranial pressure.<sup>9</sup> Any of these symptoms may also occur with a brain tumor. In this case, our patient did experience one severe headache a few days prior to the examination. Our patient also had a fourth nerve palsy, but this finding was longstanding, associated with the presence of a longstanding head turn. As her binocularity had never been able to develop, she would not have had new symptoms of diplopia as possible evidence of the presence of this neurological condition. Fortunately, following this patient regularly for her strabismus and monitoring ocular health allowed for early diagnosis and immediate referral for proper management.

An identifiable cause of increased intracranial pressure is not commonly found in adult IIH, but more than half of pediatric cases have been associated with an identifiable cause.<sup>10,11</sup> Frequently encountered causes include endocrine abnormalities such as Addison's disease and the prior use of recombinant growth hormone or drugs such as cytarabine (used in the treatment of cancers of white blood cells) and

all-trans retinoic acid (used to treat acne vulgaris, keratosis pilaris, and acute promyelocytic leukemia). Infections such as acute sinusitis and varicella zoster virus have been reported in association, as well as anemia.<sup>5</sup> It is important to note that this patient presented with bilateral swollen optic nerves just three months after her strabismus surgery. Upon review of the literature, there were no reports of a relationship between strabismus surgery and risk of increased intracranial hypertension, which is unlikely but an area that may warrant more research. In our case, no discernible cause was found for increased intracranial pressure, so we use prepubertal idiopathic hypertension in the true sense of the word.

It is important for practitioners to be aware that bilateral indistinct optic nerves are an emergency due to many possible grave differential diagnoses in patients of any age, such as brain or spinal cord tumors.<sup>5</sup> Clinical evaluation of patients with swollen optic nerves should begin with a thorough history including age, sex, any recent weight gain, any use of medications, any underlying medical conditions that may be associated, and whether there has been development of secondary sexual characteristics. The patient should be asked about associated symptoms such as blurred or double vision, visual disturbances, headaches, nausea, neck or back pain, and any other neurological disorders. Visual acuity, color vision, confrontation visual fields, pupillary testing, versions/ductions, and dilated fundus examination are all important aspects of the clinical examination. The absence of spontaneous venous pulsation may suggest an elevated intracranial pressure. A neurological examination should also be included. Swollen optic nerves should also be differentiated from pseudopapilledema, which is “an optic nerve head that appears swollen, but without buried blood vessels in the nerve fiber layer, peripapillary hemorrhages, cotton wool spots, Paton’s folds, or exudates.”<sup>5</sup> Pseudopapilledema can be caused by optic nerve head drusen or congenitally small, crowded discs. B-scan ultrasonography may be used to rule out optic nerve head drusen. If the child’s age and cooperation are appropriate, an automated visual field examination, optical coherence tomography (OCT), or Heidelberg retinal tomography (HRT) could be considered. Bilateral swollen optic nerves indicate the need for an MRI of the brain and orbits with and without contrast, as well as a lumbar puncture to rule out increased intracranial pressure and/or any systemic or intracranial abnormalities.

Cerebrospinal fluid pressure is an important diagnostic indicator for IIH. Normal values for CSF opening pressure are not well established in children. There are many factors that may influence opening pressure, including age, body mass index, depth of sedation, and agitation or crying at the time of testing.<sup>5</sup> Estimates in the literature have approximated an elevated opening pressure to be 180 mm H<sub>2</sub>O in children under 8 years of age.<sup>12</sup> A recent study prospectively evaluated CSF opening pressure in 197 children ages 1 to 18 years.<sup>13</sup> In this study, an opening pressure of 280 mm H<sub>2</sub>O was

considered to be abnormally elevated on the basis of the 90th percentile. In those children who were not obese and who received minimal to no sedation, an opening pressure of 250 mm H<sub>2</sub>O was considered to be elevated. According to both guidelines, our patient’s CSF opening pressure was elevated and called for treatment for resolution of her papilledema.

Children with IIH typically have a good prognosis for total resolution of symptoms if the condition is rapidly diagnosed and treated appropriately.<sup>2</sup> Treatment goals for pediatric IIH include the relief of associated symptoms and the resolution of the optic nerve edema with prevention of further loss of visual function.<sup>7</sup> A delay in diagnosis or treatment of IIH may lead to loss of visual field and visual acuity due to damage to the optic nerve. The treatment of choice for pediatric IIH is the use of acetazolamide, usually an oral dose of 15 mg/kg/day, for an average period of 4-6 months.<sup>5,7,14</sup> Occasionally, the use of furosemide 0.3-0.6 mg/kg/day or topiramate 1.5-3.0 mg/kg/day may be considered when the side effects of acetazolamide are unable to be tolerated. In cases of progressive papilledema, persistent high CSF pressure, or a decline in visual function even with aggressive medical management, surgical intervention such as optic nerve sheath fenestration and shunting procedures may be indicated.<sup>5,7</sup> In these patients, visual acuity, visual fields, and optic disc appearance should be monitored regularly with age-appropriate testing.<sup>14</sup> Compared to the more chronic nature of IIH in adults, children with IIH have a more intermittent course, with a recurrence rate of less than 22%.<sup>4,5</sup>

## Conclusion:

It is critical for clinicians to keep in mind the importance of monitoring the ocular health of all patients, including young, healthy children. Any patient may develop serious conditions without warning or symptoms, and rapid treatment and management may be essential in precluding the loss of visual function. When bilateral swollen optic nerves are present, urgent referral is indicated to rule out etiologies requiring immediate treatment. Furthermore, if increased intracranial pressure is found, the patient should receive appropriate, timely treatment to prevent damage to the optic nerves. IIH is a diagnosis of exclusion, and when no identifiable cause for increased intracranial pressure is found, the term IIH is used in its proper sense.

## References

1. Friedman DI, Jacobson DM. Diagnostic criteria for idiopathic intracranial hypertension. *Neurology* 2002;59:1492-5.
2. Dessardo NS, Dessardo S, Sasso A, Sarunic AV, Dezulovic MS. Pediatric idiopathic intracranial hypertension: clinical and demographic features. *Coll Antropol* 2010;34 Suppl 2:217-21.
3. Durcan FJ, Corbett JJ, Wall M. The incidence of pseudotumor cerebri: population studies in Iowa and Louisiana. *Arch Neurol* 1988;45:875-7.
4. Cinciripini GS, Donahue S, Borchert MS. Idiopathic intracranial hypertension in prepubertal pediatric patients: characteristics, treatment, and outcome. *Am J Ophthalmol* 1999;127:178-82.

5. Rangwala LM, Liu GT. Pediatric idiopathic intracranial hypertension. *Surv Ophthalmol* 2007;52:597-617.
6. Smith JL. Pseudotumor cerebri. *Trans Am Acad Ophthalmol Otolaryngol* 1958;62:432-40.
7. Distelmaier F, Sengler U, Messing-Juenger M, Assmann B, et al. Pseudotumor cerebri as an important differential diagnosis of papilledema in children. *Brain & Development* 2006;28:190-5.
8. Phillips PH, Repka MX, Lambert SR. Pseudotumor cerebri in children. *J AAPOS* 1998;2:33-8.
9. Speer C, Pearlman J, Phillips PH, et al. Fourth cranial nerve palsy in pediatric patients with pseudotumor cerebri. *Am J Ophthalmol* 1999;127:236-7.
10. Scott IU, Siatkowski RM, Eneyni M, et al. Idiopathic intracranial hypertension in children and adolescents. *Am J Ophthalmol* 1997;124:253-5.
11. Youroukos S, Psychou F, Fryssiras S, et al. Idiopathic intracranial hypertension in children. *J Child Neurol* 2000;15:453-7.
12. Fishman RA. *Cerebrospinal fluid in diseases of the nervous system*, 2nd ed. Philadelphia, PA: Saunders, 1992.
13. Avery RA, Shah SS, Licht DJ, et al. Reference range for cerebrospinal fluid opening pressure in children. *N Engl J Med* 2010;363:891-3.
14. Phillips PH. Pediatric pseudotumor cerebri. *International Ophthalmology Clinics* 2012;52:51-9.

---

*Correspondence regarding this article should be emailed to Divya Nandwani, OD at [dnandwani0513@gmail.com](mailto:dnandwani0513@gmail.com). All statements are the authors' personal opinions and may not reflect the opinions of the representative organizations, ACBO or OEPF, Optometry & Visual Performance, or any institution or organization with which the authors may be affiliated. Permission to use reprints of this article must be obtained from the editor. Copyright 2015 Optometric Extension Program Foundation. Online access is available at [www.acbo.org.au](http://www.acbo.org.au), [www.oepf.org](http://www.oepf.org), and [www.ovpjournal.org](http://www.ovpjournal.org).*

Nandwani D, Vricella M, Richter S. Pediatric idiopathic intracranial hypertension: A case report. *Optom Vis Perf* 2015;3(4):227-32.

---

***The online version of this article  
contains digital enhancements.***