

# Article ▶ Causes of Retinal Hemorrhages and Papilledema in Young Children

Jenna M. Liechty, OD, Greenwood, Indiana

## ABSTRACT

**Background:** There is much debate on the implications of retinal hemorrhages observed in young children. The location and type of retinal hemorrhages can have important diagnostic significance in determining the cause, especially when there is suspicion of child abuse. Additionally, when retinal hemorrhages present with papilledema in children, it is a challenge to distinguish whether they are mutually exclusive or connected by a single etiology.

**Case Report:** A three-year-old African American female presented for her first eye examination with complaints of tearing for one week. Binocular indirect ophthalmoscopy revealed bilateral disc edema, a pre-retinal hemorrhage OS, and scattered peripheral intraretinal hemorrhages OU. The patient was referred to the emergency room at LeBonheur Children's Hospital for MRI of head, neck, and orbits and for a neurology consult. MRI results confirmed papilledema and showed a subdural hemorrhage surrounding the left parietal and occipital lobes.

**Discussion:** Due to the potential serious nature of possible etiologies, a prompt referral was made in this case and is the standard of care. It is also important for optometrists to recognize the different types of retinal hemorrhages and the implications they have in the course of the disease process, as well as to be familiar with the protocols for reporting suspected child abuse if it is potentially occurring.

**Keywords:** children, papilledema, retinal hemorrhages, subdural hemorrhage

## Introduction

The implications of retinal hemorrhages in young children have sparked much debate and remain a controversial topic. Historically, retinal hemorrhages have been associated with child abuse, particularly with shaken baby syndrome.<sup>1</sup> When retinal hemorrhages present with papilledema in a young child, it is often difficult to distinguish whether the two findings are mutually exclusive or connected. A broad knowledge base is required correctly to interpret retinal hemorrhages and potential causes of papilledema in children by being familiar with the different types of retinal hemorrhages, their diagnostic significance, and differential diagnosis.

## Retinal Hemorrhages

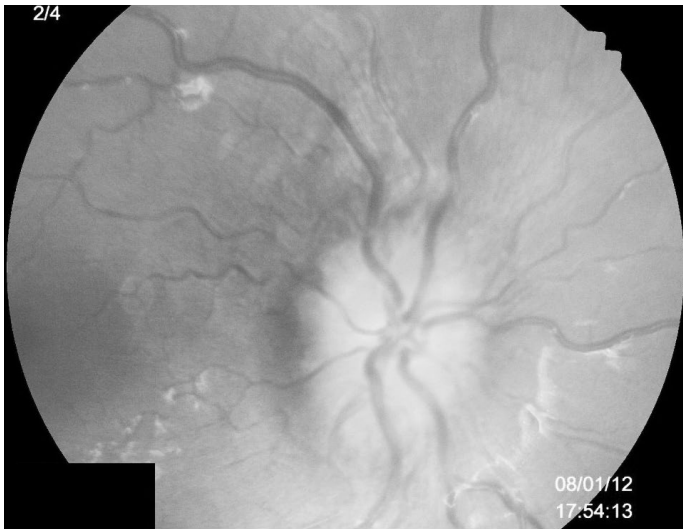A working knowledge of the various types and locations of retinal hemorrhages is required, as different types of retinal hemorrhages are associated with different etiologies. Retinal hemorrhages, from posterior to anterior, can be classified as subretinal, intraretinal, pre-retinal (subhyaloid), and vitreous hemorrhages.

Subretinal hemorrhages are located between the photoreceptors and retinal pigment epithelium (RPE) and can be derived from either retinal or choroidal circulation.<sup>1</sup> They often appear as red blotches underneath elevated retina and are typically extensive. Reabsorption is often slow, taking as long as several months, and a pale yellow exudate often remains. These hemorrhages can interfere with the function of the choriocapillaris, which nourishes the outer retinal layers and may be associated with a permanent central scotoma.<sup>1</sup>

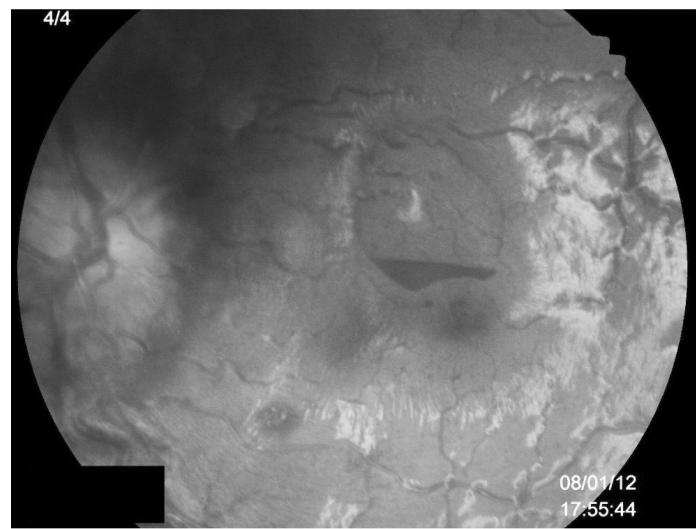
Intraretinal hemorrhages can be divided into two categories: superficial and deep. Superficial intraretinal hemorrhages originate from the capillary bed located between the nerve fiber layer and ganglion cell layer.<sup>1</sup> They spread along the path of least resistance along the nerve fibers, which are more tightly bunched near the optic nerve, giving rise to the elongated, frayed appearance and thus being called “splinter” and “flame” type hemorrhages.<sup>1,2</sup> More peripherally, superficial intraretinal hemorrhages form a more rounded appearance and have a tendency to clear quite rapidly.<sup>1</sup> Deeper intraretinal hemorrhages, including “dot” and “blot” hemorrhages, originate from the deep capillary layer and can involve the inner or outer nuclear layer.<sup>1,2</sup> Dot hemorrhages tend to fragment and fade over the course of several weeks. Blot hemorrhages have a rounded appearance, are often full-thickness retinal hemorrhages, and may be associated with venous occlusion and retinal ischemia.<sup>1</sup>

When pre-retinal hemorrhages form, blood lies underneath the inner limiting membrane and originates from superficial capillaries. Early pre-retinal hemorrhages form a round mass, most dense in the center. Over time the red blood cells sink to the bottom of the mass, giving a boat-shaped or crescent appearance, where the most inferior portion has the densest color.<sup>1</sup>

Vitreous hemorrhages occur when large retinal or pre-retinal hemorrhages break through the vitreous gel; all but the most severe vitreous hemorrhages clear spontaneously, although mild vitreous hemorrhages can still obscure vision. When recurrent vitreous hemorrhages occur in children



**Figure 1:** Disc edema of right optic nerve



**Figure 2:** Disc edema of left optic nerve, pre-retinal hemorrhages, and scattered intraretinal hemorrhages

younger than seven years of age, it is necessary to monitor for deprivation amblyopia.<sup>1</sup>

### Papilledema

Papilledema is the hallmark of increased intracranial pressure (ICP) and is thought to be the result of disrupted axoplasmic flow and capillary non-perfusion. When increased ICP is present, there is a concomitant dilation of the optic nerve sheath. This subsequently allows communication between intracranial and subarachnoid spaces with the optic nerve sheath.<sup>2</sup> It has been hypothesized that increased ICP can compress the central retinal vein within the optic nerve sheath, leading to resistance of venous outflow and thus causing retinal hemorrhages. Papilledema from increased intracranial pressure can be differentiated from bilateral optic disc swelling with a lumbar puncture. Pseudopapilledema can be distinguished from true papilledema by clinical observation, optical coherence tomography, and ultrasound. Additionally, other causes of papilledema can be ruled out with laboratory testing and neuroimaging.<sup>2</sup>

### Case Report

A three-year-old African American female was brought in by her aunt for her first eye exam. Her aunt, who was her legal guardian for the past year, noticed tearing in both eyes for one week. The medical and ocular history was unknown. A fall was reported by the child's guardian, but details were unclear in the initial case history. A recent mild fever due to a cold was reported. She was not taking any medications.

### Pertinent Findings

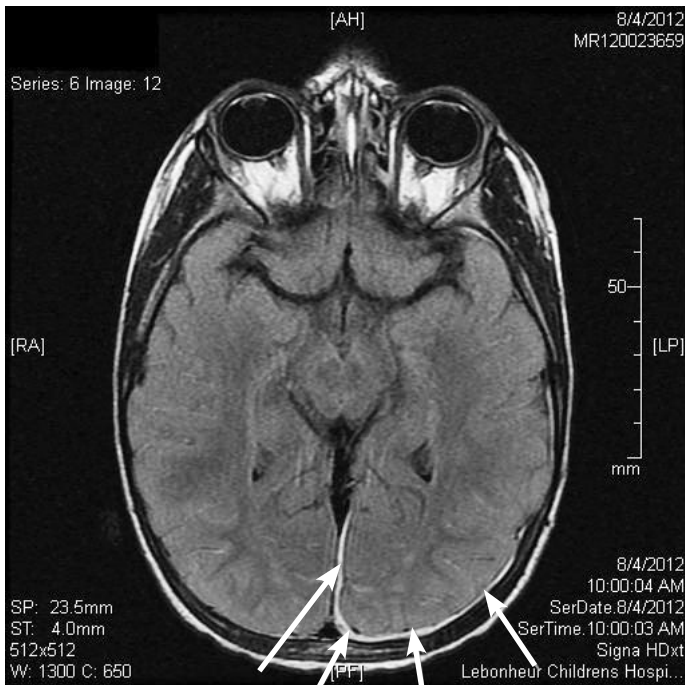
Entering distance visual acuity was 20/30 OD, OS and 20/25 OU with Lea symbols. Near visual acuity was 20/30 OU with Lea symbols. Ocular motility and pupils were unremarkable, and intraocular pressures were equal to palpation OU. No neurological abnormalities were noted.

Anterior segment evaluation revealed epiphora OU, trace papillae in the inferior palpebral conjunctiva OU, and patent puncta OU. Posterior segment evaluation revealed bilateral disc edema, a pre-retinal hemorrhage superior to the macula of the left eye, and scattered peripheral intraretinal hemorrhages in both eyes (Figures 1 and 2). There were no apparent signs of trauma. The patient appeared lethargic but responsive.

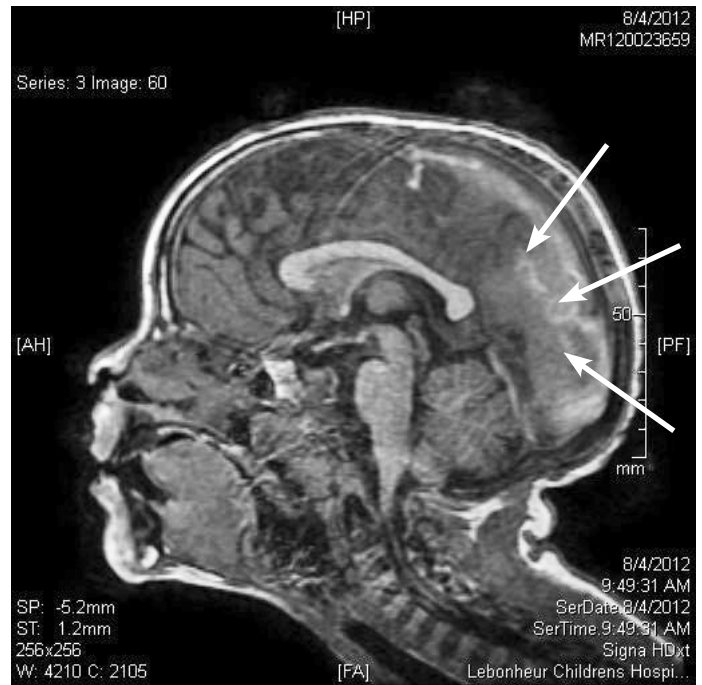
When asked about recent sickness, the patient's guardian reported that the child had a recent cold with a mild fever several weeks prior. In light of the severe findings, the guardian was further questioned about the reported fall. She stated that the child had fallen and hit the back of her head approximately 10 days prior and had complained of a headache in the occipital region for several days. She was not present during the fall and was unable to give additional circumstances surrounding the incident.

### Treatment/Management

Fundus photos were taken, and the patient was referred to the emergency room at LeBonheur Children's Hospital for MRI of head, neck, and orbits and for a neurology consult. MRI results confirmed papilledema and showed a subdural hemorrhage surrounding the left parietal and occipital lobes (Figures 3, 4, and 5). The collection of blood was reported to be no more than 3 mm in thickness, and it was not causing significant mass effect. Serial MRI was done to assess the intracranial bleeding, which was neither improving nor worsening. The remainder of the brain parenchyma was normal in appearance, without signs of hydrocephalus. Lumbar puncture opening pressure was measured at 50 cm H<sub>2</sub>O, presumably increased due to the space-occupying hemorrhage. Normal opening pressure is considered to be less than 20-25 cm H<sub>2</sub>O. There was no evidence of brainstem herniation or skull fracture. Laboratory testing, including blood chemistry, white cell counts, glucose/protein monitoring, metabolic panel, and CSF cultures, were within expected normal ranges.



**Figure 3:** T1 weighted image showing subdural hemorrhage (white arrows)



**Figure 4:** T1 weighted image of subdural hemorrhage (white arrows)

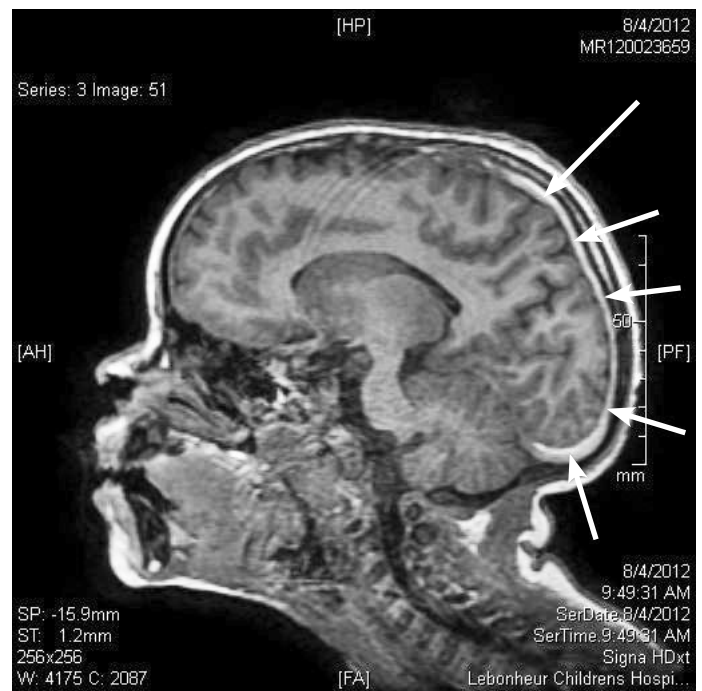
### Follow up

Follow up and continued documentation of the retinal hemorrhages can be important in cases where there is risk of decreased vision secondary to a vitreous hemorrhage. Even if vision is not affected, assuring there are no new hemorrhages present is critical, especially if non-accidental trauma is considered as a diagnosis. While retinal hemorrhages cannot be used in determining the time and date of the injury, fading retinal hemorrhages are unlikely to have occurred in the past several hours.<sup>3</sup> Wide-spread superficial hemorrhages or small dot hemorrhages can resolve in as little as 24 hours, and hemorrhages involving multiple layers of the retina are unlikely to last weeks or months.<sup>2,4</sup> If a traumatic schisis cavity is present, blood can spread into the vitreous within one to three days.<sup>5</sup> As a result, careful follow up is necessary because intervening vitrectomy may be necessary. Papilledema in children often resolves after three to six months of medical treatment. Depending on the etiology, papilledema can last for several months and potentially lead to optic atrophy.<sup>6</sup>

Due to the need of close monitoring, our patient was scheduled for a repeat dilated fundus examination 1 month after the referral to the emergency room. She unfortunately did not show for the follow up appointment. After multiple attempts were made to reach the patient's guardian by phone and mail, Child Protective Services became involved. In ideal circumstances, follow up dilated fundus examinations in such cases would be scheduled in order to document resolution of the retinal hemorrhages, to monitor for vitreous hemorrhages, and to assure that there are no new hemorrhages present.

### Discussion

The leading diagnosis was papilledema with bilateral retinal hemorrhage from accidental trauma; due to the poor history



**Figure 5:** T1 weighted image of subdural hemorrhage (white arrows)

surrounding the fall in light of severe findings, non-accidental trauma could not be ruled out. Other differential diagnoses included idiopathic intracranial hypertension, leukemia, viral neuroretinitis, anemia, Terson syndrome, and metabolic and clotting syndromes (Table 1). When considering a case such as the one presented, it is important to take into consideration the symmetry of the hemorrhages, the history, and the presence of other ocular signs to assist in diagnosis and making the appropriate referral.

**Table 1: Differential diagnosis of retinal hemorrhages presenting with papilledema in young children**

Etiologies	Characteristics of retinal hemorrhages	Other associated ocular/systemic findings
<b>Non-accidental trauma</b>	Bilateral (unilateral and asymmetry also recognized) <sup>1,5,9</sup> Peripheral distribution <sup>5,9</sup> Intraretinal most common and often involve all retinal layers <sup>1</sup> Pre-retinal and vitreous hemorrhage more specific for non-accidental trauma <sup>1,9</sup>	Macular retinoschisis <sup>2,5</sup> Lethargy <sup>5</sup> Changes in mental status <sup>9,10</sup> External signs of trauma (bruising, etc.) <sup>5,10,11</sup> Intracranial bleeding <sup>5</sup>
<b>Accidental trauma</b>	Unilateral, few in number <sup>14</sup> Rare, unless found after motor vehicle accidents or crushing injury <sup>1,5,13</sup>	External signs of trauma <sup>11</sup> Orbital roof fractures <sup>13</sup>
<b>Idiopathic intracranial hypertension</b>	Peripapillary flame hemorrhage <sup>2,5</sup> Pre-retinal near optic nerve <sup>5</sup>	Papilledema <sup>2,7</sup> Headache (62-91% of cases) <sup>7</sup> Diplopia <sup>7</sup> Nausea/vomiting <sup>7</sup>
<b>Leukemia</b>	Posterior pole distribution <sup>1</sup> Favors deep retinal layers <sup>1</sup> Dot-blot, flame-shaped, white-centered <sup>15</sup>	Optic disc swelling <sup>15</sup> Dilated, tortuous vessels <sup>1,15</sup> Yellowish cast to retinal arteries and veins <sup>1</sup> Cotton wool spots <sup>1,15</sup> Isolated cranial nerve palsies <sup>15</sup>
<b>Infectious neuroretinitis</b>	Splinter hemorrhages <sup>18</sup>	Optic disc swelling (unilateral most common) <sup>16,20</sup> Macular star <sup>16,20</sup> Parinaud's oculoglandular syndrome <sup>19</sup> Lymphadenopathy <sup>19,20</sup>
<b>Anemia</b>	Bilateral, Intraretinal <sup>1,6</sup> May have white-centered hemorrhage <sup>1</sup> Mild, <sup>4</sup> confined to posterior pole <sup>2</sup>	Bilateral optic disc swelling <sup>1</sup> Dilated, tortuous retinal veins <sup>1</sup> Cotton wool spots <sup>1</sup>
<b>Terson syndrome</b>	Few, located near optic disc <sup>5</sup> Confinement to posterior pole <sup>17</sup> Retinal or vitreous hemorrhage <sup>17,21</sup>	Papilledema <sup>3</sup> Intracranial bleeding <sup>3,15,19</sup> Macular holes <sup>19</sup> Retinal detachment <sup>19</sup>
<b>Coagulopathy</b>	Few in number <sup>5</sup> Non-specific <sup>2,6</sup>	Subdural hemorrhage <sup>15</sup>
<b>Glutaric aciduria</b>	Few in number <sup>5</sup> Confined to posterior pole <sup>5</sup> Sparse intraretinal and preretinal <sup>11</sup>	Subdural hemorrhage after minor trauma <sup>3</sup>

### Non-accidental Trauma

Retinal hemorrhages have long been linked with child abuse and non-accidental trauma.<sup>8</sup> Previous studies indicate that 40% of abused children have retinal hemorrhages, with estimates as high as 65-89%, which make retinal hemorrhages the most common ocular manifestation of abuse.<sup>1,5</sup> Additionally, retinal hemorrhages are 60% more likely to be seen in children with non-accidental head trauma, as opposed to 10% in children with accidental trauma.<sup>9</sup> Unfortunately, children with intracranial injury who present with co-existent retinal hemorrhage are significantly more likely to have inflicted brain injury rather than non-inflicted brain injury.<sup>8</sup> There is also evidence that papilledema is uncommon in non-accidental head injury (<10%), which makes determining a diagnosis difficult.<sup>6</sup>

The location of the retinal hemorrhages can also give insight in helping to determine the etiology. Green and colleagues studied the eyes of 23 children who had died of intentional trauma, 12 of whom had retinal hemorrhages. The most common site of retinal hemorrhages was at the ora serrata (40%); posterior pole, including near optic disc and macula (20%), was the second most common site. The remaining 40% were distributed in the remaining regions of the retinal periphery. These findings correlate with retinal anatomy, as the

vitreous attaches to the retina at the ora serrata and optic disc.<sup>22</sup> The distribution of the retinal hemorrhages has implications in both the diagnosis and pathophysiology. Peripheral retinal hemorrhages are often indicative of acceleration-deceleration injury.<sup>5</sup> While these findings are consistent with multiple lines of research that have shown that the major cause of severe retinal hemorrhages is vitreoretinal traction, there is much debate as to what types of forces can cause retinal hemorrhages in non-accidental trauma.<sup>6</sup> It has been reported that in addition to acceleration-deceleration forces, direct blows to the head and thoracic compression as in sexual abuse can both cause retinal hemorrhages, although the subject remains controversial.<sup>1</sup>

Other ocular findings can assist in pointing the clinician in the right direction towards a diagnosis. Other ocular findings in non-accidental trauma can include traumatic retinoschisis, retinal detachment, and lens dislocation.<sup>23-25</sup> Traumatic macular retinoschisis in children under five years of age has only been observed in non-accidental trauma and in fatal crush injuries to the head, and thus can serve as a diagnostic finding.<sup>5,6</sup> Care must be taken in determining traumatic macular retinoschisis from pre-retinal or subhyaloid hemorrhage. In traumatic macular retinoschisis, the inner limiting membrane (ILM) and/or nerve fiber layer (NFL) is pulled away by the vitreous. Deeper schisis cavities can also occur. Pre-retinal hemorrhage occurs

when blood accumulates in the subhyaloid space between the posterior vitreous face and the retina or under the ILM. A traumatic schisis is often surrounded by a hypopigmented or hemorrhagic circumferential line or elevated perimacular circular folds, which are absent in a pre-retinal hemorrhage.<sup>5,6</sup> While challenging to differentiate, optical coherence tomography (OCT) can be a useful tool in distinguishing the two clinical entities. Additionally, vitreous hemorrhages, otherwise rare, are also found in non-accidental trauma, as well as other conditions such as leukemia and anemia.<sup>1</sup>

The findings of retinal hemorrhage with brain injury should be a red flag that further investigation is needed. Other presenting factors must be taken into consideration when there is a possibility of non-accidental trauma as the diagnosis. Well-known risk factors for non-accidental trauma include young parents, unstable family situations, low socioeconomic status, and disability of the child.<sup>8</sup> The clinical presentation can reflect the severity of the injury and ranges from mild lethargy or irritability to acute life-threatening events, seizures, coma, or death.<sup>7</sup> In the case presented, non-accidental trauma could not be ruled out. When non-accidental trauma is high on the list of differentials, one must proceed with caution, since an injury pattern is rarely pathognomonic for abuse or accident without careful consideration of the explanation provided.<sup>6,11</sup>

### **Accidental Trauma**

Short falls can also cause serious injury, including subdural hemorrhage. While these findings are rare, child abuse specialists have acknowledged that retinal hemorrhage and other retinal damage can occur as well.<sup>12</sup> The estimated incidence of retinal hemorrhages associated with accidental injury, including falls, varies from zero to 3%.<sup>5</sup> Other studies have also concluded that retinal hemorrhages are very rare in accidental injury. When such hemorrhages are present, they are generally found only after severe head trauma, such as motor vehicle accidents where there is other severe bodily injury.<sup>5,13</sup> In 1992, Buys and colleagues prospectively studied 70 children under three years old who had head injuries and who underwent ophthalmological examination within 48 hours of the injury. It was determined that 75 of the 79 children suffered head injuries from accidental trauma, including falls from various heights and falls down the stairs. None of the children with accidental head injuries had retinal hemorrhages. However, retinal hemorrhages were present in four children who had head injuries due to non-accidental injury.<sup>26</sup>

Other studies involving children with confirmed accidental trauma, some of whom experienced intracranial hemorrhage, show a very low rate of retinal hemorrhage (0% to 3%).<sup>6</sup> Trenchs and colleagues also studied 154 patients admitted to the hospital with a diagnosis of head trauma from a vertical fall. One hundred twenty-two (79.2%) patients had skull fractures, 16 (10.4%) had intracranial injuries, and 3 (1.9%) had retinal hemorrhages, which were all unilateral and associated with epidural hemorrhage.<sup>14</sup> Other studies have

reported that retinal hemorrhages associated with accidental trauma are typically characterized by a small number of pre-retinal or intraretinal hemorrhages confined to the posterior pole and occasionally out to the mid-periphery.<sup>6</sup> When retinal hemorrhages are present with a history of minor trauma, it is important to investigate underlying medical conditions, as well as to rule out the possibility of non-accidental trauma.<sup>13</sup>

### **Idiopathic Intracranial Hypertension**

Papilledema is a classic finding in idiopathic intracranial hypertension. While retinal hemorrhages may also occur, there is substantial evidence that increased intracranial pressure will not cause extensive retinal hemorrhages.<sup>2</sup> The postulated mechanism by which both increased intracranial and intrathoracic pressure would cause retinal hemorrhage is by increased resistance or obstruction to venous outflow from the eye. When retinal hemorrhages are present, they are often peripapillary flame hemorrhages and/or they follow a pattern of venous distribution.<sup>5</sup> Other abnormalities, including visual field defects, diplopia from cranial nerve palsies, and headaches, may also be observed.<sup>7</sup> In the case presented, the cause of the increased intracranial pressure was not idiopathic but rather was from the space-occupying subdural hemorrhage. Idiopathic intracranial hypertension is a diagnosis of exclusion and fortunately paints a clinical picture that is easily distinguished from non-accidental trauma.

### **Leukemia**

Retinal hemorrhages are common in patients with leukemia. Dilated and tortuous veins are often seen; arteries and veins can take on a yellowish cast, reflecting the decreasing proportion of red blood cells and concurrent increase in white blood cells.<sup>15</sup> Other ocular findings include vitreous hemorrhage, optic disc swelling, and cotton wool spots. The formation of retinal hemorrhages in leukemia is thought to be caused by neoplastic cells infiltrating the retina and damaging the retinal vessel walls, impairing coagulation and increasing viscosity. The retinal hemorrhages found in leukemia tend to occur at the posterior pole and are found in all layers of the retina, while most common in the deeper layers of the retina. Some hemorrhages may have a white center, resembling a Roth spot, which represent a collection of leukemic cells, platelet and fibrin aggregates, or septic emboli.<sup>1</sup> While the findings vary depending on the severity of disease, blood work and systemic work-up are needed to rule out the possibility of leukemia as a diagnosis. In the case presented, normal blood work results ruled out leukemia as a diagnosis.

### **Neuroretinitis**

Neuroretinitis can be caused by a variety of organisms, including *Bartonella henselae* in cat-scratch disease, various nematodes, and in rare cases, the protozoan *Toxoplasma gondii*.<sup>16</sup> Sub-acute vision loss with optic neuropathy and retinal exudates in a pathognomonic macular star formation

has been well documented in the literature. Persistent lymphadenopathy is often present, with non-specific flu-like illness. The characteristic stellate maculopathy may not always be evident at the time of presentation.<sup>16</sup> Diagnosis is facilitated by a thorough history, such as recent cat scratches, exposure to other potential infectious agents, and serological testing to confirm whether increased titer levels are present. The history and blood work made neuroretinitis an unlikely diagnosis in the case presented.

### **Anemia**

Retinal hemorrhages and bilateral optic disc swelling can be seen in anemic children. As hematocrit in red blood cells decreases, retinal veins become dilated and tortuous, with multiple bilateral intraretinal hemorrhages, some of which may have white centers. Most retinal hemorrhages in anemia have dot, blot, flame, or splinter appearances. Other ocular findings include vitreous hemorrhage, optic disc swelling, and cotton wool spots. It is important to note that among anemic patients, adults are more likely to develop retinal hemorrhages than are children. Blood work can confirm a diagnosis of anemia; in the case presented, the patient did not appear to be anemic.<sup>1</sup>

### **Terson Syndrome**

Terson syndrome is defined as intraocular hemorrhage in the setting of intracranial hemorrhage. Due to the low incidence of intracranial hemorrhage in children, Terson syndrome has not been well studied in this age group.<sup>17</sup> The pathogenesis of Terson syndrome remains controversial. It is unclear whether a rapid increase in intracranial pressure can produce impairment of venous return through the cavernous sinus and intraocular venous stasis followed by intraocular hemorrhage, or whether blood in the retrobulbar optic nerve sheath directly enters the subhyaloid space.<sup>10,17</sup> Previous study considers the maximal prevalence of Terson syndrome in children with intracranial hemorrhage to be 8%.<sup>10</sup> Spontaneous Terson syndrome is a differential diagnosis for children with intraocular hemorrhage with suspected abusive head trauma.<sup>2</sup> It also can be associated with papilledema, which makes Terson syndrome a plausible diagnosis in the case presented.<sup>5</sup>

### **Clotting and Metabolic Disorders**

Retinal hemorrhages have been reported in various blood disorders, including sickle cell disease and malaria. When present, the retinal hemorrhages are usually few in number and confined to the posterior pole.<sup>5</sup> Clotting disorders, such as von Willebrand disease, that may lead to various degrees of bleeding tendency can produce subdural hemorrhage and retinal hemorrhage.<sup>2</sup> One case demonstrates misdiagnosis of child abuse when the child had a clotting disorder.<sup>18</sup> Type 1 glutaric aciduria is a rare autosomal-recessive metabolic disorder which is sometimes associated with subdural hematoma after minor head trauma.<sup>5</sup> The hallmark of this condition is preexisting macrocephaly. Basal ganglia disease

confirmed with neuroimaging helps distinguish this disorder from non-accidental head trauma. Laboratory testing can easily distinguish metabolic and clotting disorders from other etiologies that may cause retinal hemorrhages. The patient did not appear to have any metabolic or clotting disorders.

### **Referrals**

When abuse is suspected, the appropriate action needs to be initiated to prevent further abuse from occurring. Forty-eight states, the District of Columbia, American Samoa, Guam, the Northern Mariana Islands, Puerto Rico, and the Virgin Islands designate professions whose members are mandated by law to report child maltreatment.<sup>27</sup> Individuals designated as mandatory reporters typically have frequent contact with children. Such individuals may include social workers, teachers, principals, and other school personnel; physicians, nurses, and other health-care workers; counselors, therapists, and other mental health professionals; child care providers; medical examiners or coroners; and law enforcement officers.<sup>27</sup>

The circumstances under which a mandatory reporter must make a report vary from state to state. Typically, a report must be made when the reporter, in his or her official capacity, suspects or has reason to believe that a child has been abused or neglected.<sup>27</sup> Another standard frequently used is in situations in which the reporter has knowledge of, or observes a child being subjected to, conditions that would reasonably result in harm to the child.

Most states maintain toll-free telephone numbers for receiving reports of abuse or neglect.<sup>28</sup> Reports may be made anonymously to most of these reporting numbers, but states find it helpful to their investigations to know the identity of reporters.<sup>29</sup> Eighteen states, the District of Columbia, American Samoa, Guam, and the Virgin Islands currently require mandatory reporters to provide their names and contact information, either at the time of the initial oral report or as part of a written report.<sup>27</sup>

If abuse is suspected, many resources are available. Childhelp is a national organization that provides crisis assistance and other counseling and referral services. The Childhelp National Child Abuse Hotline is staffed 24 hours per day, 7 days per week, with professional crisis counselors who have access to a database of 55,000 emergency, social service, and support resources. Reports can be made by calling the National Child Abuse Hotline at 1-800-4ACHILD (1-800-422-4453), and all calls are anonymous. Another useful resource is [www.childwelfare.gov](http://www.childwelfare.gov), which provides resources in child abuse reporting by state.<sup>28</sup>

Many cases of child abuse and neglect are not reported, even when mandated by law. Therefore, nearly every state and U.S. territory imposes penalties, often in the form of a fine or imprisonment, on mandatory reporters who fail to report suspected child abuse or neglect as required by law.<sup>29</sup> Upon conviction, a mandated reporter who fails to report can face jail terms ranging from 30 days to 5 years, fines

ranging from \$300 to \$10,000, or both jail terms and fines. While optometrists need to be aware of the potential legal and financial consequences of failing to report, there are also moral obligations that should be considered when reporting child abuse, in order to be an advocate for our young patients.

## Conclusion

In the case presented, it is not clear whether the papilledema, retinal hemorrhages, and subdural hemorrhage are connected by a single etiology. After an investigation prompted by Child Protective Services, it was ultimately determined that the subdural hemorrhage in the case described was accidental secondary to the fall, although non-accidental trauma still remains plausible. While retinal hemorrhage in the presence of subdural hemorrhage was historically pathognomonic to diagnose non-accidental trauma, these findings can also result from a number of traumatic or medical conditions. Additionally, subdural hemorrhage can occur with both accidental and non-accidental trauma. Many of these conditions present with additional ocular and systemic findings which can assist in determining the diagnosis, in addition to laboratory testing and systemic work-up to rule out other causes. Careful and thorough documentation of retinal hemorrhages and other ocular pathology is pertinent. Because of the convoluted nature of such cases, it may be necessary for social services to become involved in order to prevent further abuse if it is occurring. Timely, appropriate referral is necessary in all young children with signs of papilledema to rule out brain pathology with neuroimaging. It is important to note that 50% of children with inflicted brain injury had presented with previous signs of physical abuse that had been missed. Clinicians in all settings need to be aware of the clinical indicators for non-accidental trauma, while optometrists specifically need to be familiar with the different causes of retinal hemorrhages and papilledema in order to make the appropriate referral.

## References

1. Aryan HE, Ghosheh FR, Jandial R, Levy ML. Retinal hemorrhage and pediatric brain injury: Etiology and review of the literature. *J Clin Neurosci* 2005;12:624-31.
2. Levin AV. Retinal hemorrhage in abusive head trauma. *Pediatrics* 2010;126:961-70.
3. Duhaime AC, Alario AJ, Lewander WJ, Shut L, et al. Head injury in very young children: Mechanisms, injury types and ophthalmic findings in 100 hospitalized patients younger than 2 years of age. *Pediatrics* 1992;90:179-85.
4. Emerson MV, Pieramici DJ, Stoessel KM, Berreen JP, Gariano RF. Incidence and rate of disappearance of retinal hemorrhages in newborns. *Ophthalmol* 2001;108:36-9.
5. Forbes BJ, Rubin SE, Margolin E, Levin AV. Evaluation and management of retinal hemorrhages in infants with and without abusive head trauma. *JAAPOS* 2010;12:267-73.
6. Levin AV. Retinal hemorrhages: advances in understanding. *Pediatr ClinNorth Am* 2009;6:333-44.
7. Rangwala LM, Liu GT. Pediatric idiopathic intracranial hypertension. *Surv Ophthalmol* 2007;52:597-617.
8. Fung ELW, Sung RY, Nelson EA, Poon WS. Unexplained subdural hematoma in young children: Is it always child abuse? *Pediatr Int* 2002;44:37-42.
9. Bechtel K, Stoessel K, Leventhal JM, Ogle E, et al. Characteristics that distinguish accidental from abusive injury in hospitalized young children with head trauma. *Pediatrics* 2004;114:165-8.
10. Maguire S, Pickerd N, Farewell D, Mann M, et al. Which clinical features distinguish inflicted from non-inflicted brain injury? A systematic review. *Arch Dis Child* 2009;94:860-7.
11. Kellogg ND. Evaluation of suspected child physical abuse. *Pediatrics* 2007;119:1232-41.
12. Gabauff SC. Challenging the pathophysiologic connection between subdural hematoma, retinal hemorrhage and shaken baby syndrome. *West J Emerg Med* 2011;12:144-58.
13. Sturm V, Knecht PB, Landau K, Menke MN. Rare retinal hemorrhages in translational accidental head trauma in children. *Eye* 2009;23:1535-41.
14. Trenchs V, Curcoy AI, Morales M, Serra A, Navarro R, et al. Retinal haemorrhages in head trauma resulting from falls: Differential diagnosis with non-accidental trauma in patients younger than 2 years of age. *Childs Nerv Syst* 2008;24:815-20.
15. Sharma T, Grewal J, Gupta S, Murray PI. Ophthalmic manifestations of acute leukaemias: The ophthalmologist's role. *Eye* 2004;18:663-72.
16. Kuckukerdonmez C, Akova YA, Yilmaz G. Ocular toxoplasmosis presenting as neuroretinitis: Report of two cases. *Ocul Immunol Inflamm* 2002;10:229-34.
17. Bhardwaj G, Jacobs MB, Moran KT, Tan K. Terson syndrome with ipsilateral severe hemorrhagic retinopathy in a 7-month-old child. *JAAPOS* 2010;14:441-3.
18. Stray-Pederson A, Omland S, Nedregaard B, Klevberg S, et al. An infant with subdural hematoma and retinal hemorrhages: does von Willebrand disease explain the findings? *Forensic Sci Med Pathol* 2011;7:37-41.
19. Sobha S, Reck AC, Evans A. Neuroretinitis associated with cat scratch disease in a child. *Clin Exp Ophthalmol* 2000;28:127-8.
20. Reddy AK, Morriss MC, Ostrow GI, Stass-Isern M, et al. Utility of MR imaging in cat-scratch neuroretinitis. *Pediatr Radiol* 2007;37:840-3.
21. Ko F, Knox DL. The ocular pathology of Terson's syndrome. *Ophthalmol* 2010;117:1423-9.
22. Green MA, Lieberman G, Milroy CM, Parsons MA. Ocular and cerebral trauma in non-accidental injury in infancy: Underlying mechanisms and implications for paediatric practice. *Br J Ophthalmol* 1996;80:282-7.
23. Kaur B, Taylor D. Fundus hemorrhages in infancy. *Surv Ophthalmol* 1992;37:1-17.
24. Clark RSB, Orr RA, Atkinson CA, Towbin RB, Pang D. Retinal hemorrhages associated with spinal cord arteriovenous malformation. *Clin Pediatr (Phila)* 1995;34:281-3.
25. Sandramouli S, Robinson R, Tsaloumas M, Wilshaw HE. Retinal haemorrhages and convulsion. *Arch Dis Child* 1997;76:440-51.
26. Buys YM, Levin AV, Enzenauer RW, et al. Retinal finding after head trauma in infants and young children. *Ophthalmol* 1992;99:1718-23.
27. Mandatory Reporters of Child Abuse and Neglect. Child Welfare Information Gateway. August 2012. <http://1.usa.gov/lxcfy69> Last Accessed May 19, 2013.
28. How to report suspected child maltreatment. US Department of Health and Human Services. Child Welfare Information Gateway. <http://1.usa.gov/1Ei2ZoR> Last Accessed May 19, 2013.
29. Penalties for Failure to Report and False Reporting of Child Abuse and Neglect. Child Welfare Information Gateway. August 2012. <http://1.usa.gov/1ynfMnK> Last Accessed May 19, 2013.

---

*Correspondence regarding this article should be emailed to Jenna Liechty, OD, at [jmliechty@gmail.com](mailto:jmliechty@gmail.com). All statements are the author's personal opinions and may not reflect the opinions of the representative organizations, ACBO or OEPE, Optometry & Visual Performance, or any institution or organization with which the author may be affiliated. Permission to use reprints of this article must be obtained from the editor. Copyright 2014 Optometric Extension Program Foundation. Online access is available at [www.acbo.org.au](http://www.acbo.org.au), [www.oepf.org](http://www.oepf.org), and [www.ovpjournal.org](http://www.ovpjournal.org).*

Liechty JM. Causes of retinal hemorrhages and papilledema in young children. *Optom Vis Perf* 2014;2(6):307-13.

---

***The online version of this article contains digital enhancements.***