Psychiatric Illness, Binocular Vision Anomalies and Optometric Vision Therapy

Dominick M. Maino, OD, MEd, FAAO, FCOVD-A [*+]; Stephanie Lyons, OD [+]; Kelsey Frederick, OD [+]; Stephen Best, MD [^]; Dan Pavel, MD [^]
[*] Illinois College of Optometry, [+] Lyons Family Eye Care; Chicago, Il [^] The Neuroscience Center, Deerfield, Il

3241 South Michigan Avenue, Chicago, Illinois 60616

BACKGROUND

Little to nothing is known about the oculo-visual problems associated with psychiatric illness; let alone what the therapeutic impact of optometric vision therapy may be upon those with various mental and binocular vision disorders. What is known is that chronic disability, including functional visual impairment, can cause depression and other psychological problems. We know that uncorrected strabismus adversely affects the mental state of the individual. We know that those with a developmental disability and a psychiatric illness are often prescribed ten or more major psychotropic/neuroleptic medications and that these pharmaceutical agents can have multiple adverse effects upon the individual's functional vision abilities as well. What we do not know is how a program of Optometric Vision Therapy can positively affect the quality of life of these individuals. This case series is a preliminary investigation into this yet un-researched area.

CASE SERIES

This case series reports on the diagnostic data, therapy utilized and treatment outcomes for 3 adults with one or more psychiatric illnesses and binocular vision problems. Two of the patients also had neuro-imaging by a neuro-psychiatrist. This neuroimaging (Brain SPECT: Single Photon Emission Computed Tomography) is a simple, non-invasive Nuclear Medicine procedure which can detect functional changes in various gray matter locations (in contradiction to the structural changes detected by MRI, CT, ect.). It does so by mapping the blood flow distribution in both the cortical and subcortical gray matter areas of the brain. The results are displayed in a 2D and 3D color rendition of relative perfusion maps. The color code indicates the level of blood flow which is proportional to the metabolism level. This enables the detection of hyper or hypo functioning areas from lowest levels (blue hues) to highest level (white and black surrounded by white e.g. the "bull's eye").

CASE #1:

GC is a 41 y/o WM had been previously diagnosed with exotropia, accommodative dysfunction and oculomotor dysfunction at another office. His reading ability was severely affected being associated with numerous symptoms (including headache). He was in medical school but could not pass boards because of his vision and psychiatric problems and was then dismissed from medical school. CG was accepted back into school a few years later. He has now successfully graduated from a medical school and has passed boards. Unfortunately he was not accepted into a residency at this time and is currently working as a research assistant.

He is bipolar, has an anxiety disorder and has been diagnosed with attention problems for which he is taking several medications. His functional vision problems include diplopia, constant headache, convergence insufficiency, intermittent exotropia and saccadic eye movement disorder.

CASE #2:

CR, a 23 y/o WM, was referred by a neuropsychiatrist who recommended a functional vision assessment. CR thought that he may have Asperger Syndrome, but his psychiatrist said there was no sign of this in his brain scans. CR was diagnosed with a mood disorder, attention anomalies, dyspraxia and visuomotor problems. He is currently going to college (studying organization and communication) and is working at a large retail store. He also likes to read. CR enjoys wearing his contact lenses, but switches between spectacles and his contacts often. He has been diagnosed with convergence insufficiency, saccadic eye movement deficiencies and accommodation spasm/excess. CR was referred to a COVD colleague for therapy so the therapy outcomes are not yet available.

CR's brain SPECT analysis shows areas of under function (red arrows) and several areas of hyper function (white arrows) as well. Since he reported significant reading problems, the neuropsychiatrist referred him for an optometric functional vision assessment.

Figure 1: CR's brain SPECT analysis noted both hyper (white) and hypo-perfusion (red).

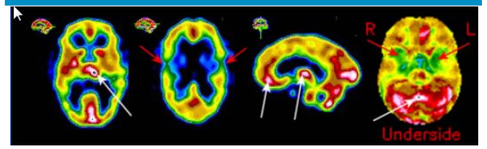

Figure 2: CMC's Brain SPECT analysis show areas of hyper (white) and hypo-perfusion (red)

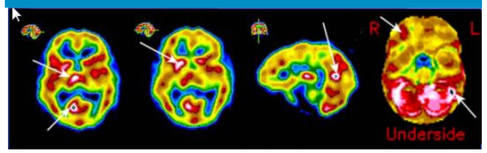

Table 1: Vision Therapy Sequence

Monocular	Biocular	Binocular	Integration/Stabilization
Oculomotor	Oculomotor	Oculomotor	Oculomotor+Accommodative+
Accommodation	Accommodation	Accommodation	vergence+Hand-eye
Hand-eye	Hand-eye	Hand-eye	simultaneously
	Anti-suppression	Anti-suppression	
		Vergence	

CASE #3:

MC, a 26 y/o WM, was referred by a neuropsychiatrist for possible binocular vision disorders. He takes several medications for a psychiatric disorder and attentional problems which overall seem to help. During the neuropsychiatric evaluation and brain SPECT analysis it was noted that a number of significant areas of hyper function (white arrows) was present. Upon completion of the clinical history, interview and additional testing, this patient was diagnosed as having psychosis, depression and attentional anomalies. The neuropsychiatrist also noted that he had difficulties reading and was advised to seek out a functional optometric vision assessment. Functional vision problems included convergence insufficiency and accommodative insufficiency

Table 2: Case History/Complaints

Pre-Therapy Case History/Complaints

GC	CR	MC
Exotropia	Depression	Headaches
OMD	Anxiety	Can't read (pain)
Acc Dysf	ADHD	Psychosis
Can't Read	Depression	ADHD
Headaches	Fractured spine	QoL=43
Blurred vision	Wears CLs	Seldom leaves home
Eyes hurt	Numerous symptoms	Depression
Closes eyes	Dyspraxia	
Diplopia	Visual-motor anomalies	
Bi-polar		
Anxiety		
ADHD		
QoL=43		

Post-Therapy Case History/Complaints

GC	CR	MC
All vision problems	Under colleagues care	All vision problems
improved or eliminated		improved or
He can now read		eliminated
No diplopia		QoL=16
QoL=27		Goes into

DISCUSSION

Our brains, even those of us with a psychiatric disorder, can demonstrate experience dependent change (neuroplasticity) throughout life. Unfortunately, when it comes to those with a psychiatric disorder little is known about the presence of binocular vision disorders and how optometric vision therapy can alter their visual abilities and quality of life.

Table 3:
(not all tests were given at all evaluations. (Ocular health unremarkable. Only VT patients noted here)

Initial Findings

GC Examination Findings (not all tests were given at all evaluations. (Ocular health unremarkable. Only VT patients noted here)

BVA (OD/OS)	Refractive Error	Stereo/WAD	EOMS/Pursuits/Saccades	CT	NPC	Phoria (N)	Vergences (N)	Acc
20/20-20/20	-.75-.25132	+Random Dot	Full/+2/+2	30 IAXT near	Diplopia RL	10BI near	None BI/BO	AM MEM
	-1.50-.25X025	4-5 W4D Alt		IAXT near	34/36"		Diplopia	Variable
Post Vision Therapy								
20/20; 20/20	-.75-.25132	+Random Dot	Full/+3/+3 -undershoot	12 XOP near	3/ 4" RL	5 BI near	BI 10/B	+1.00
	-1.50-.25X025	5/10 Wirt Circles		No strab noted			BO 25/20	
		4 W4D Dist/Near						

MC Examination Findings (not all tests were given at all evaluations. (Ocular health unremarkable)

BVA (OD/OS)	Refractive Error	Stereo/WAD	EOMS/Pursuits/Saccades	CT	NPC	Phoria (N)	Vergences (N)	Acc
20/20; 20/20	-1.75	-Random Dot	Full/+3/+3	16 EXP near	20/22" RL	6 BO	4/1 BO 6/2 BI	MEM AM/+1.00
	-1.75-.50X013	2/10 Wirt Circles						Facility Acc Blur
		Variable/Suppression						
		4W4D variable						
Post Vision Therapy								
20/20; 20/20	-1.75	+ Random Dot	Full/+4/+4	Ortho	To Nose	2 BI	40/25 BO	MEM + .75
	-1.75-.50X013	4 W4D Dist/Near					10/6 BI	
							(No suppression)	
								Facility
								8 CPM (+/-2.00)

Table 4: Medications

CR	GC	MC
Risperdal	Vyvanse	Clozapine
Cymbalta	Celebrex	
Adderall	Adderall	

Table 5: Clinical Findings

Initial Clinical Findings

CR
Head tilt to right
(OD anatomically higher than OS)
Convergence Insufficiency
Accommodative Spasm
Saccadic Eye Movement Dysfunction
COVD QoL: 27
TOVA API: 4.64 (normal)
Visagraph: fixation, average span of recognition, Oculo-motility

GC
Convergence Insufficiency
Visual Pursuits
Saccades
Intermittent Alternating Exotropia

COVD QoL: 43
TOVA API: 2.29 (Overall findings not normal)
Visagraph: fixations, regressions
average span of recognition, reading
rate, saccades, oculomotility,
visual tracking

MC
Convergence Insufficiency
Accommodative Insufficiency
COVD QoL: 43

Those with a psychiatric illness and binocular vision problems face many obstacles. These include the lack of knowledge about the association of mental illness with various functional vision anomalies, biases of health care professionals when working with those with a disability (especially those with a psychiatric illness), and the patient's emotional and behavioral status.

All of the patients in this case series had significant vision problems. The two patients that underwent optometric vision therapy showed significant improvement in signs and symptoms and on their QoL scores. This improvement may also be associated with a heightened quality of personal functioning and quality of life.

For example, MC (#3) had an initial COVD Quality of Life (QoL) Survey Score of 19. The second time he filled out the QoL survey and after he had an opportunity to observe his visual behavior more closely, he scored a 43. Upon the completion of vision therapy, this patient's QoL score was 16, all subjective complaints resolved/improved and functional vision problems eliminated. He is now, with some coaching, starting to go out into the community more frequently as well. GC (#1) will soon complete his vision therapy program and now notes that reading is much easier and symptom free. His initial QoL score was 43 and now is as low as 27.

The role that brain SPECT imaging analysis plays in the assessment of functional vision problems is unknown. It is currently utilized to assess various brain, heart and bone disorders. The neuropsychiatric disorders typically imaged include dementia, stroke, seizures, epilepsy, and head injuries. Since many of these disorders are associated with functional vision anomalies, further study of using these tools to aid the functional optometrist's approach to care should be investigated.

CONCLUSION

All should have access to functional optometric vision care, including those diagnosed with a psychiatric illness. This case series clearly indicates the possibility of vision therapy improving the signs, symptoms and quality of life of those with mental illness. Further research and an investigation of the brain SPECT imaging should be undertaken to determine additional beneficial outcomes for individuals with a psychiatric disorder.

REFERENCES

Schnell PH, Maino D, Jespersen R. Psychiatric Illness and Associated Oculo-visual Anomalies. In Taub M, Bartuccio M, Maino D. (Eds) Visual Diagnosis and Care of the Patient with Special Needs; Lippincott Williams & Wilkins. New York, NY;2012:111-124.
Amen DG. Images of human behavior: A brain SPECT atlas paperback. Mindworks Press; 2004

CONTACT INFORMATION
Dominick M. Maino, OD, MEd, FAAO, FCOVD-A
Illinois College of Optometry • 3241 S. Michigan Ave. Chicago, Il 60616
dmaino@ico.edu