Novel Use of Visually Evoked Potential (VEP) to Document Asymmetries between Hemifields following Traumatic Brain Injury (TBI)

STATE UNIVERSITY OF NEW YORK
COLLEGE OF OPTOMETRY

SUNY EYE INSTITUTE
33 West 42nd Street
New York, New York 10036

Samantha Slotnick[1], Kenneth Ciuffreda[2,3], Naveen Yadav[2,3], Robert Byne[4]

[1]Private practice, Scarsdale, NY; [2] SUNY College of Optometry, NY, NY;
[3] SUNY Eye Institute, State University of New York; [4] Family Vision Care, Mt. Kisco, NY

Procedure:

Visually Evoked Potential (VEP) measures were obtained in a patient who had sustained a traumatic brain injury (TBI) to the left pinna. Subjective complaints of a softening of details on the right side of faces directed a modification of the VEP settings to explore differences in brain activity with hemifield-stimulation.

The Diopsys® NOVA-VEP (Diopsys, Inc., Pine Brook, NJ) was employed with binocular viewing at 1m for 20' arc (64x64 check size) at 85% contrast. The stimulus was presented to one hemifield (central fixation). Occluded hemifield was presented as black. Initial measures showed a 25% (3 μV) relative amplitude deficit for the right hemifield (9.2 μV) compared to the left (12.2 μV). Full field amplitude was 24.6 μV.

Longitudinally repeated VEP measures demonstrate hemifield differences while subjective symptoms of hemifield asymmetry are present.

Simulated image of subjective perception: Photo on the left is un-altered. Photo on right demonstrates perception of subtle softening of features in the right hemifield. *For best appreciation, fixate centrally on each image in succession.*

VEP presentation

Central fixation maintained on red (spinning) wheel, 85% contrast, all conditions.



Top: **Full Field**
Bottom: **Right Field Occluded**; **Left Field Occluded**

VEP hemifield amplitudes, normalized to full field amplitude and compared over time. Reduced signal strength with left hemifield occluded (i.e., right field visually stimulated), 85% contrast, 20' arc.

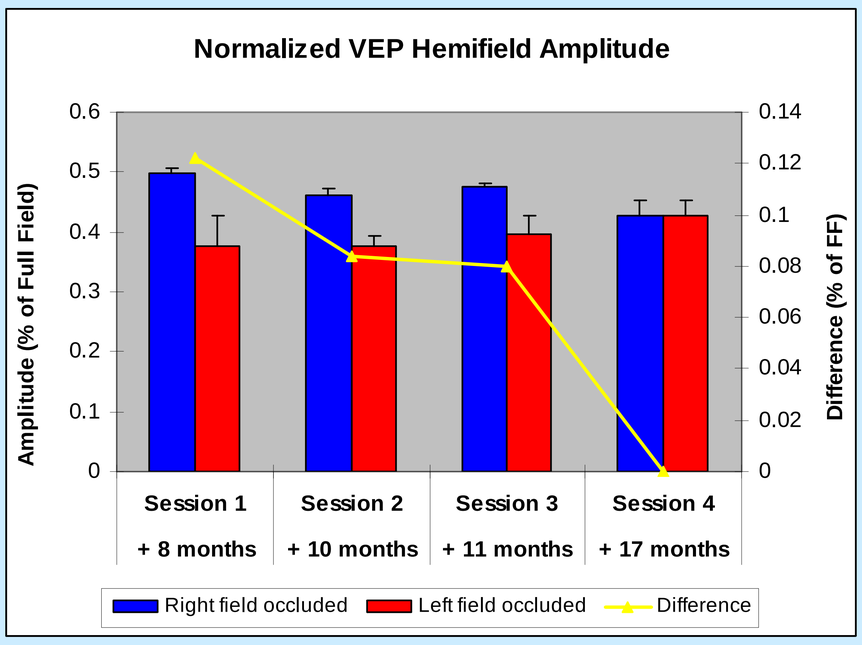

Innovative Characteristics:

Hemifield-stimulated VEP provides objective functional data in patients whose symptoms cannot be documented by other traditional methods of anatomic or functional imaging. Patients with mild TBI frequently have unremarkable findings on magnetic resonance imaging (MRI), electroencephalogram (EEG), and full-field VEP. Objective hemifield differences on VEP may correlate with subjective complaints and with performance on higher-order assessments of visual processing, such as neuropsychological testing.

Applications:

- Patients who sustain TBI, particularly with a lateralized impact, may experience asymmetric effects on visual perception.
- Sudden onset of changes in perception following TBI may be particularly disconcerting to a patient.
- Patients' ability to verbalize these effects may vary, particularly if expressive language is impacted following trauma.
- Any finding or report of subjective hemifield differences, such as hemifield neglect, would be an indication to evaluate hemifield-stimulated VEPs.
- Positive findings on hemifield-stimulated VEP may direct probing for differences in subjective perception between the two hemifields.
- Re-evaluation of asymmetry over time may provide an objective indication of recovery post-TBI.
- Medical management is supported by the ability to document physiological changes as a result of the TBI.
- Identification of objective findings which correlate with subtle subjective symptoms may provide relief to a patient who is struggling to articulate perceptual effects of the trauma.

Acknowledgments:
Thanks to Diopsys Inc, for supplying their VEP system.